

A stylized, layered silhouette of a human figure in shades of blue and purple, positioned on the left side of the cover. The silhouette is composed of several overlapping shapes, creating a sense of depth and movement. The head, torso, and limbs are clearly defined by the different layers.

HANDBOOK

for District Hospitals in Resource Constrained Settings
on Quality Assurance of Chest Radiography:
for better TB control and health system strengthening

Contents

Acknowledgments	ii
Abbreviations and Units	iii
Glossary	iv
Introduction	1
I. Why we need quality assurance of chest radiography	2
Roles of X-ray examination	2
Contribution to health system strengthening	4
What is quality assurance of chest radiography?	4
The concept of quality assessment procedure for quality chest radiography	5
Target of the Handbook and roles of TB supervisor	5
Good example of chest radiograph	7
II. How to take a good quality chest radiography	9
Fundamentals of X-ray equipment operation	9
Fundamentals of screen-film combination system	13
Fundamentals of darkroom management	15
Fundamentals of X-ray film processing technique	18
1) Manual processing	18
2) Automatic film processor	21
Specifications of X-ray equipment for chest radiography	22
Fundamentals of digital X-ray imaging system	23
III. How to assess the quality of chest radiography	26
How to use the assessment sheet	27
Simple assessment procedures of the quality of chest radiography	30
1) Identification marking of the patient	30
2) Patient positioning	32
3) Density	44
4) Contrast	47
5) Sharpness	53
6) Artifacts	55
7) Overall assessment result and actions to be taken	59
❖ Radiation protection	60
IV. How to improve the quality of chest radiography for TB control	61
Annex 1: References for further reading	63
Annex 2: Assessment sheet & summary of the simple assessment procedures	65
Annex 3: Recording form for on the spot assessment	67
Annex 4: Recording form for systematic review	68

Acknowledgments

Developed by The Tuberculosis Coalition for Technical Assistance
(TBCTA)



TBCTA Partners:



International Union Against Tuberculosis and Lung Disease



TUBERCULOSIS FOUNDATION



MANAGEMENT SCIENCES *for* HEALTH

The Global Health Bureau, Office of Health, Infectious Disease and
Nutrition (HIDN), US Agency for International Development,
financially supports this document through TB CAP under the terms of
Agreement No.GHS-A-00-05-00019-00.



USAID
FROM THE AMERICAN PEOPLE

Prepared by

Chiang Chen-Yuan, Maarten van Cleeff, Charles Daley, Takuji Date, Donald A. Enarson,
Haileyesus Getahun, Kunihiro Ito, Peter Metzger, Kosuke Okada, Ikushi Onozaki, Pedro G Suarez

Overall Coordination:

Takuji Date, Yohei Ishiguro, Kosuke Okada

Disclaimer:

Disclaimer: This document is made possible by the generous support of the American people through the United States Agency for International Development (USAID). The contents are the responsibility of TB CAP and do not necessarily reflect the views of USAID or the United States Government.

Acknowledgements:

We would like to show our appreciation to all individuals and organizations that supported this project and gave their time to develop this material. Particularly special thanks go to Dr. Mao Tan Eang, Director of the National Tuberculosis Control Program, Cambodia, and Dr. Darakshan Badar, Manager of the Provincial Tuberculosis Control Program, Punjab, Pakistan, who gave us the opportunity to field test the tools presented in this Handbook on Quality Assurance of Chest Radiography. We are also grateful to Mr. Soeung Makara, Grand Arts, for drawing the full-color, pictorial illustrations which make it easier to understand this handbook. Finally, we thank senior members of Japan Anti-Tuberculosis Association for having laid the foundation for the external quality assurance for chest radiography.

July 2008

Abbreviations and Units

Abbreviations

a-Se	amorphous selenium
a-Si	amorphous silicon
AC	alternating current
DC	direct current
CR	computed radiography
Cs(Tl)	cesium iodide doped with thallium
DOTS	directly observed therapy, short-course
DQE	detective quantum efficiency
DR	digital radiography
FFD	focus and film distance
HIV	human immunodeficiency virus
ICRU	International Commission on Radiation Units and Measurements
JATA	Japan Anti-Tuberculosis Association
ISO	International Organization for Standardization
MTF	modulation transfer function
PACS	picture archiving and communication system
RIT	Research Institute of Tuberculosis, Japan
TB	tuberculosis
TBCTA	Tuberculosis Coalition for Technical Assistance
USD	United States Dollar
WHO	World Health Organization

Units

A	ampere
°C	degrees centigrade (temperature)
cm	centimeter
kV	kilovolt
L	liter
m	meter
mA	milliampere
mAs	milliampere second
mm	millimeter
μm	micrometer
Ω	ohm: electric impedance
s	second
V	volt
W	watt

Glossary

amorphous selenium (a-Se): A material used in a direct digital X-ray detector.

amorphous silicon (a-Si): A material used in a direct digital X-ray detector.

anode: A part of the inside the X-ray tube which generates the X-ray beam.

anterior: A part of the body that is situated towards the front of another part. Anterior means the opposite of 'posterior'.

artifacts: Marks on a radiograph that are foreign to the real image, such as scratches, fingerprints, static and etc.

bucky: A device that is a part of the X-ray equipment unit which contains the moving grid system for reducing unnecessary scattered radiation. Bucky is a commonly used word of abbreviation of the Potter-Bucky moving grid system.

cassette: A light-tight holder that contains a pair of intensifying screens and an X-ray film.

cesium iodide thallium [CsI(Tl)]: The material used in an indirect digital X-ray detector.

computed radiography (CR): Digital radiography technology which uses a phosphor-based plate.

contrast: The difference between the light and dark areas of a radiograph.

density: The degree of blackening of an X-ray film caused by X-ray exposure.

detective quantum efficiency (DQE): The absolute value of signal-to-noise ratio which quantifies image contrast.

diaphragm: The muscle between the lungs and the stomach.

digital radiography: A broadly used term that refers to the electric capture of radiographic images.

effective focal size: The size of the projected area from the X-ray tube anode which generates the X-ray beam.

Exp. Date: The 'expiration date' is the date when the warranty ends for a certain quality of X-ray film, developing solution or fixing solution.

exposure: The amount of radiation produced from the X-ray tube by pre-set factors such as kV, mA and seconds.

grid: A device for absorbing unnecessary scattered radiation.

grid ratio: The ratio of the height of lead strips to the distance between radiolucent strips.

high-frequency inverter generator: A generator which produces a high frequency output of AC voltage through the inverter from the rectified DC power input.

impedance: The electrical resistance to AC circuits.

intensifying screen: Radiation sensitive fluorescent material placed inside a cassette on either side of the film that emits blue or green light when exposed to X-ray.

lung periphery: The area on the edges of the lung field.

mediastinum: The body parts located between the right and left lungs. On the chest X-ray, the trachea and thoracic vertebrae are mainly projected in the mediastinum area.

modulation transfer function (MTF): The absolute value of spatial resolution which quantifies image sharpness

posterior: A part of the body that is situated towards the back of another part. Posterior means the opposite of ‘anterior’.

pulmonary TB: Tuberculosis infection in the lung fields.

quality assessment: A method for measuring the efficacy of the chest radiograph used for improving imaging quality.

quality assurance: A system designed to continuously improve the quality of chest radiography.

quality control: All activities routinely performed by staff at each health facility for improving the quality of chest radiography.

quality improvement: The process of using the information gained through assessment to improve the quality of chest radiography.

radiographer: The job title of a person who is trained to take radiographs. According to the level of qualification, it may be termed X-ray technician, radiological technician, or radiological technologist in different countries.

safe light: Light for use inside a darkroom, which does not effect the X-ray film.

scapula: The medical term for the bone of the shoulder blade.

scattered radiation: The X-ray radiation which has changed its direction because of some physical phenomenon in the subject exposed to the X-ray. Scattered radiation causes deleterious effects to the contrast of X-ray imaging.

sharpness: The degree of appearance of the edge between two density areas in the imaging subject.

sterno-clavicular joints: The medical term for the joints between the breast bone and two clavicle bones.

TB suspect case: patient with respiratory symptoms suggestive of TB (cough and cold for more than 15 days).

thoracic vertebrae: The medical term for twelve backbones placed between the neck and stomach which connect to the rib bones.

trachea: The medical term for respiratory passage to the lungs.

X-ray: A kind of electromagnetic radiation used to visualize the inside of the body for diagnostic purposes.

X-ray engineer: The job title of a person who is trained to repair and maintain an X-ray equipment unit.

X-ray tube: A device that is a part of an X-ray equipment unit that contains an anode and a cathode for generating the X-ray beam.

X-ray tube current: The current flowing in the X-ray tube during an exposure. It is one of the radiographic exposure factors which controls the intensity of radiation and affects image density. The unit of X-ray tube current is the mA.

X-ray tube voltage: The electric voltage to the X-ray tube during an exposure. It is one of the radiographic exposure factors which controls the quality of the X-ray radiation and affects image contrast. The unit of X-ray tube voltage is the kV.

Introduction

The clinical applications of X-ray began almost immediately following the discovery of X-rays by Wilhelm Conrad Roentgen in 1895. Since then, diagnostic X-ray equipment has developed considerably and the imaging quality of X-ray examination has been greatly improved and the methods have been widely disseminated. In particular, chest radiography is the most common examination to be used as one of the initial steps to diagnose pulmonary disease including respiratory infection with tuberculosis (TB). The role of chest radiography for TB patients has gained increasing importance; especially as HIV associated TB and childhood TB are less likely to show positive smears. However, it is unfortunate that even the most basic X-ray examination in many developing countries is scarcely available and/or the quality of chest radiography is often unacceptable for diagnosing TB patients.

The rationale behind this handbook is that many faulty diagnoses by chest radiography may be associated with inappropriate radiological techniques and applications, and that improvement of imaging quality of chest radiography benefits not only the patients infected by TB but also those suffering from various pulmonary diseases. In terms of detection and treatment of pulmonary TB patients, poor imaging quality may be more harmful to patients than having the patients not diagnosed through X-ray examination at all.

The main scope of this handbook is to provide a simple way to assess the quality of chest radiograph as well as fundamentals of chest radiography, and to lead to conducting quality assurance for chest radiography even in resource constrained settings. To be concrete, based on the assessment made at the district hospital, the next steps will focus on the improvement of the quality of chest radiographs on the spot. And then, the handbook deals with quality assurance for chest radiography achieved through a well-organized effort which will be made by TB supervisors together with physicians and radiographers at the health facilities. The target group for this handbook is the TB supervisors at district and intermediate level who are not specialists in X-ray equipment, radiological technology and clinical interpretation of chest radiographs.

Improving the quality of radiography at district level will also lead to improvement of diagnosis of diseases other than TB and of traumatic injuries. Therefore, TB control programs and their partners should participate actively in both country-led and global efforts to improve action across all major areas of health systems, including policy, human resources, financing, management, service delivery and information systems.

In addition, as a considerable future option to improve the quality of radiological examinations, the introduction to digital radiographic technology and its advantages and disadvantages are also described in this handbook.

I. Why we need quality assurance of chest radiography

Roles of X-ray examination

Bacteriological investigation of sputum is the best way of diagnosing TB, since the demonstration of TB bacilli is conclusive. As for the visualization of TB bacilli, microscopic examination is considered the most reliable and inexpensive means to be used in TB case finding because TB bacilli are too small to be seen with the naked eye. On the other hand, radiological pulmonary investigation, namely chest radiography, can be used to observe the location and aspect of the illness, and therefore it has been a common method for visualizing chest diseases around the world.

Roles of radiological chest examinations have been limited especially in TB control until now due to some drawbacks such as observer error, over- or under-reading, and disagreement between readers. Chest radiography is a highly sensitive technique for diagnosing pulmonary TB in immunocompetent individuals, even though it is unspecific, since TB has no pathognomonic signs. The role of the chest radiography in the diagnosis of TB is dependent on the available resources and on TB prevalence in the population. In poorer countries it is recommended to use chest radiography in TB suspected cases with three negative sputum smear microscopy results in which there is no response to antibiotic treatment. (For further information on the International Standards for Tuberculosis Care, please refer to the following URL: http://www.tbcta.org/TB_CAP_Toolbox/ and the citation from the reference number 1 and 2 in Annex 1.)

However, the HIV epidemic and dual infection of TB and HIV are now altering the role of radiological chest examinations in TB control. The role has been gaining increasing importance; especially as HIV associated TB and childhood TB are less likely to show positive smears. In addition, chest radiography plays a significant role in shortening delays in diagnosis and should be performed early in the course of investigation of TB suspects among seriously ill cases infected with HIV. To do so, the limitations that exist on the wider use of chest radiography, such as resource constraints to equip district hospitals with X-ray equipment and difficulty of interpreting results, need to be addressed.

On the other hand, chest radiograph with poor image quality can cause misdiagnoses or require repeated examinations, wasting economic resources and exposing patients to unnecessary radiation. Consequently, providing high quality imaging of chest radiograph benefits anyone who will be examined by X-ray, and the precise control of these X-ray images is an important task for the radiographers; radiological technologists or radiological technicians.

In order to achieve good quality of radiological chest examinations, cooperation among these 5 main cadres of staff is critical: TB supervisors, physicians, radiographers, logistics managers, and X-ray engineers from the manufacturer and/or local agents. *Figure 1.1* and *Table 1.1* show the responsibility of services for these 5 main cadres.

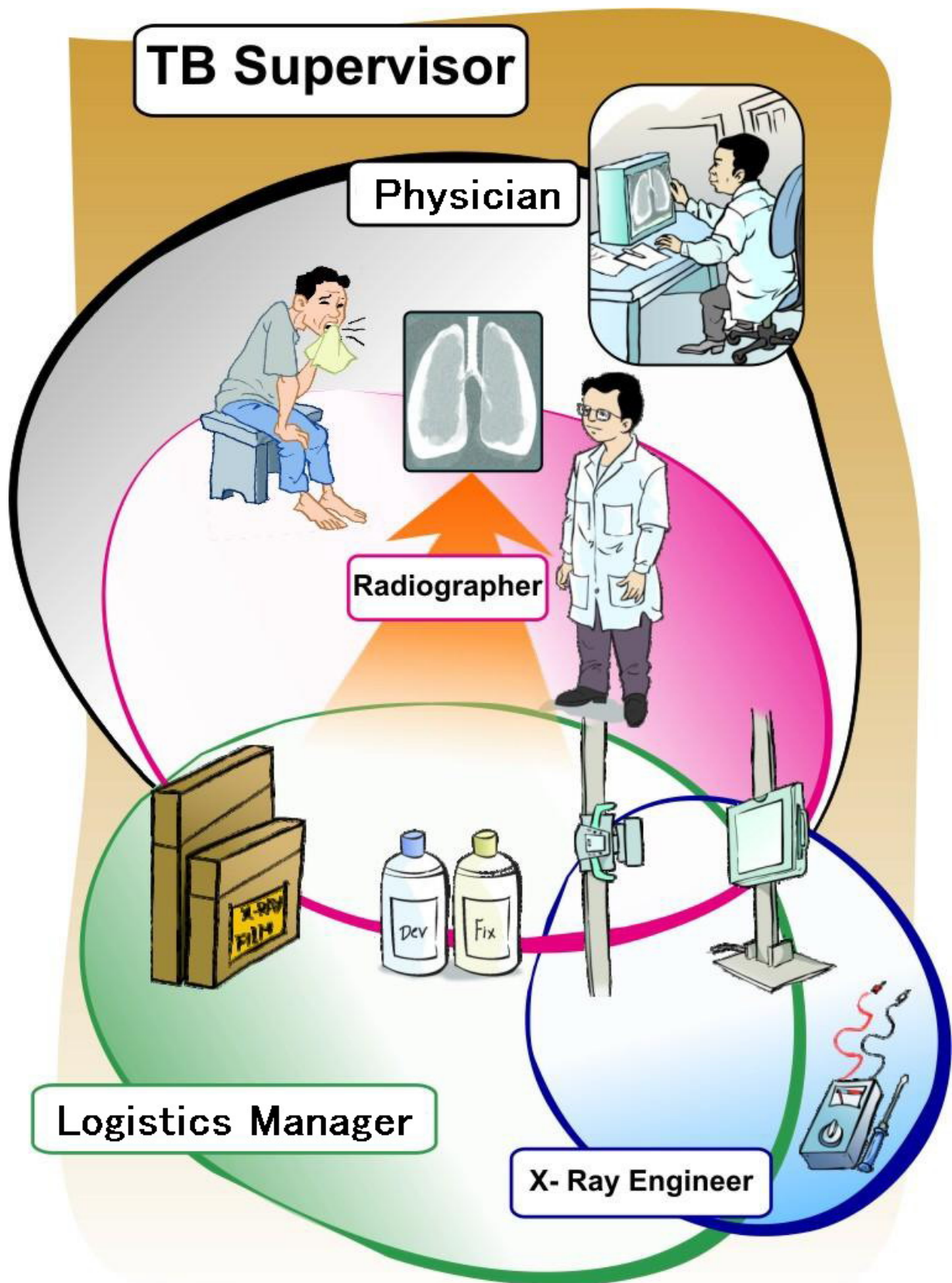


Figure 1.1 Illustration shows the responsibility for 5 cadres

Contribution to health system strengthening

Health system strengthening is defined as ‘improving capacity in some critical components of health systems, in order to achieve more equitable and sustained improvement across health services and outcomes’. TB control programs and their partners should participate actively in both country-led and global efforts to improve action across all major areas of health systems, including policy, human resources, financing, management, service delivery (including infrastructure and supply systems) and information systems.

Pulmonary TB is often manifested as a cough and cold, and people with TB symptoms first present to primary care services as respiratory patients. By linking TB control activities to proper management of all common respiratory conditions, TB programs and the staff who implement TB services at local level can help to improve the quality of care and the efficiency with which it is provided. In this context, improving the quality of chest radiography and skills of radiographers working at health facilities will lead to proper diagnosis not only of TB, but also of other respiratory diseases including community acquired pneumonia among adults or children and opportunistic lung infections among people infected with HIV. Additionally, other radiological examinations in areas other than the lungs are required for diagnosing traumatic injuries including traffic accidents

(For further information on health system strengthening, please refer to the following URL; http://www.who.int/tb/health_systems/participation_innovations/en/ and the citation from the reference number 3 in Annex 1.)

What is quality assurance of chest radiography?

Quality Assurance in this handbook is a system designed to continuously improve the quality of chest radiography at a health facility or at a district served by more than one health facility, and it can be achieved through organized efforts by all staff members involved in taking or reading the chest radiograph. It comprises Quality Control, Quality Assessment, and Quality Improvement. Quality Control includes all quality control efforts routinely performed by staff at each health facility, such as regular maintenance or checking of X-ray equipment, accessory devices, and chemicals and consumables. Quality Assessment is the measurement of the level of quality of chest radiograph, for example, the comparison of one set of measurements against a ‘gold standard’. Quality Improvement is the process of using the information gained through assessment to improve quality, with the key component of data collection, data analysis, and creative problem solving. It includes continuous monitoring and evaluation, identifying defects and retraining of staff for prevention of recurrent problems. In other words, we can only achieve quality assurance through quality control, quality assessment, and quality improvement. Pointing out the assessment result of a chest radiograph to staff is not the end but the means.

What is important in the assessment procedure is to seek the source of the problem and to take the steps to improve, so that in the end the quality of the chest radiograph will be improved. It is the objective of this handbook to provide concrete ideas for further

improvement of the quality of chest radiography in collaboration with radiographers and chest physicians in the health facilities.

The concept of quality assessment procedure for quality chest radiography

Our aim is to provide a simple and more practical on-site assessment method, which is readily available even in resource-limited settings and can be easily used by TB supervisors and radiographers, and moreover, that is based on objective evaluation to some extent.

The method presented in this handbook originated from the one which was developed by the Research Institute of Tuberculosis, Japan Anti-Tuberculosis Association.

Target of the Handbook and roles of TB supervisor

In order to achieve good quality radiological chest examinations, cooperation among these 5 main cadres of staff is critical: TB supervisor, physicians or clinical officers, radiographers, logistics manager, and X-ray engineers from the manufacturer and/or local agents. The target of the handbook is mainly TB supervisors who are responsible for TB control at the district and intermediate levels, but as mentioned earlier, quality assurance of chest radiography should not be only their responsibility, but also that of each staff involved in film taking or reading, including physicians, radiographers, logistics managers, and X-ray engineers. Therefore, the handbook consists of three pillars;

- **How to take a good quality chest radiograph**
- **How to assess the quality of chest radiographs**
- **How to improve the quality of chest radiographs**

The first part in particular will be useful for each staff to understand the fundamentals of chest radiography.

Figure 1.1 and *Table 1.1* show the responsibility of services for these 5 main cadres. TB supervisors should have responsibility for quality assurance of chest radiography at a whole district under their jurisdiction as well as at a health facility. At each facility radiographers may be engaged in most parts of the job, but physicians themselves who are interpreting the X-ray films must have interest in the quality of chest radiography and point out any problems to be addressed.

Although *Table 1.1* does not include roles of the National TB Program and staff at central or intermediate level, needless to say, their roles are crucial in both ensuring and developing the human resources. To put activities such as quality improvement or quality assurance into practice, some training courses need to be planed and conducted at the central or intermediate level.

Table 1.1 Responsibility of health care workers for *Quality Assurance of Chest Radiography*

Responsibility		TB supervisor	Physician	Radio-grapher	Logistics manager	X-ray engineer
Quality Assessment for chest radiograph		✓	✓	✓	---	depends
Activities for Quality Control	Positioning of patients	---	depends	✓	---	---
	Record of X-ray examinations	---	---	✓	---	---
	Regular maintenance for X-ray unit and accessories	---	---	✓	---	depends
	Consumables storage	depends	---	✓	depends	---
	Procurement of consumables for X-ray examination	---	---	✓	✓	---
	Repair & calibration of X-ray unit	---	---	---	---	✓

Good example of chest radiograph

The sample imaging below shows a chest radiograph of excellent quality (Figure 1.2).

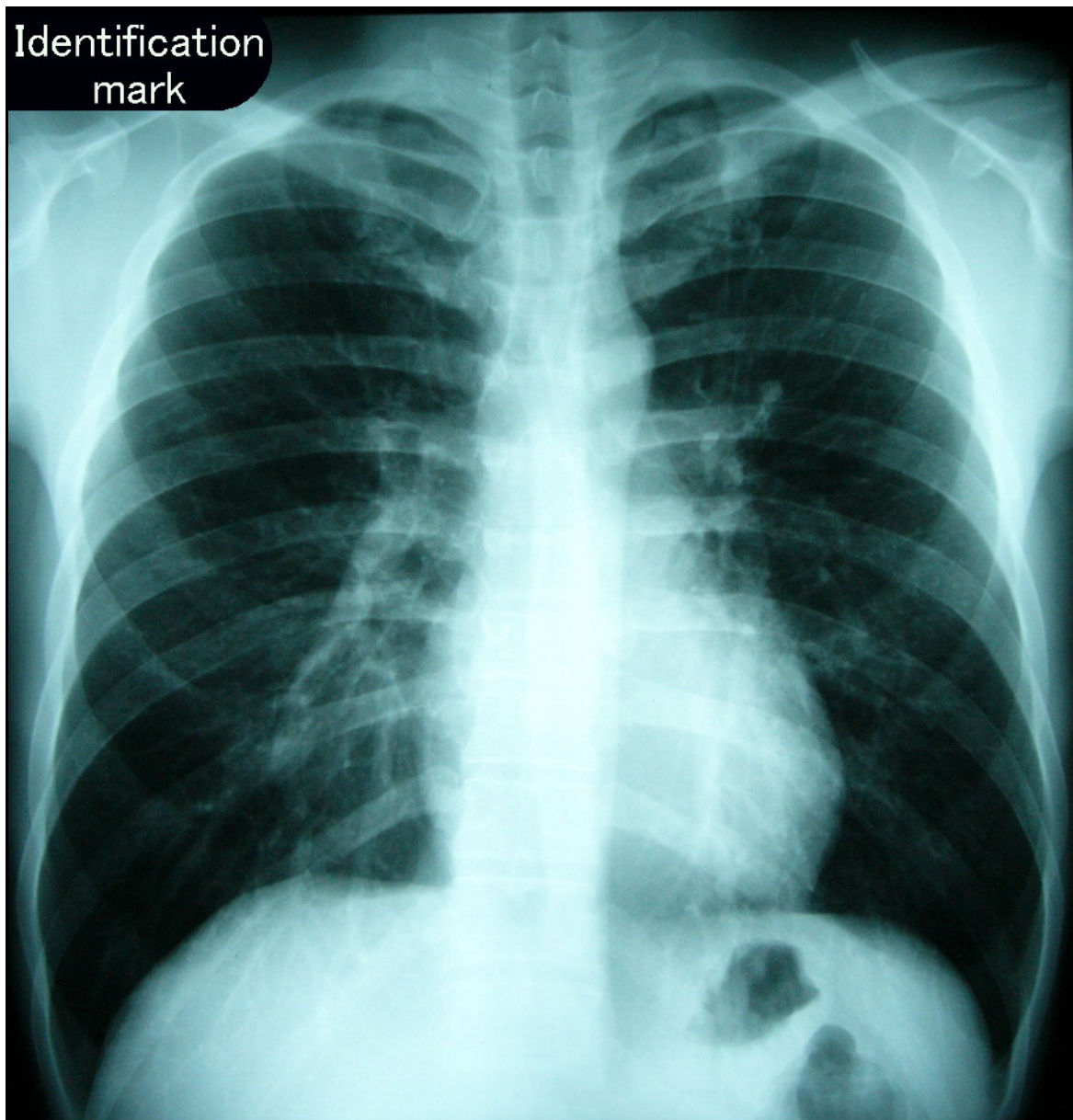


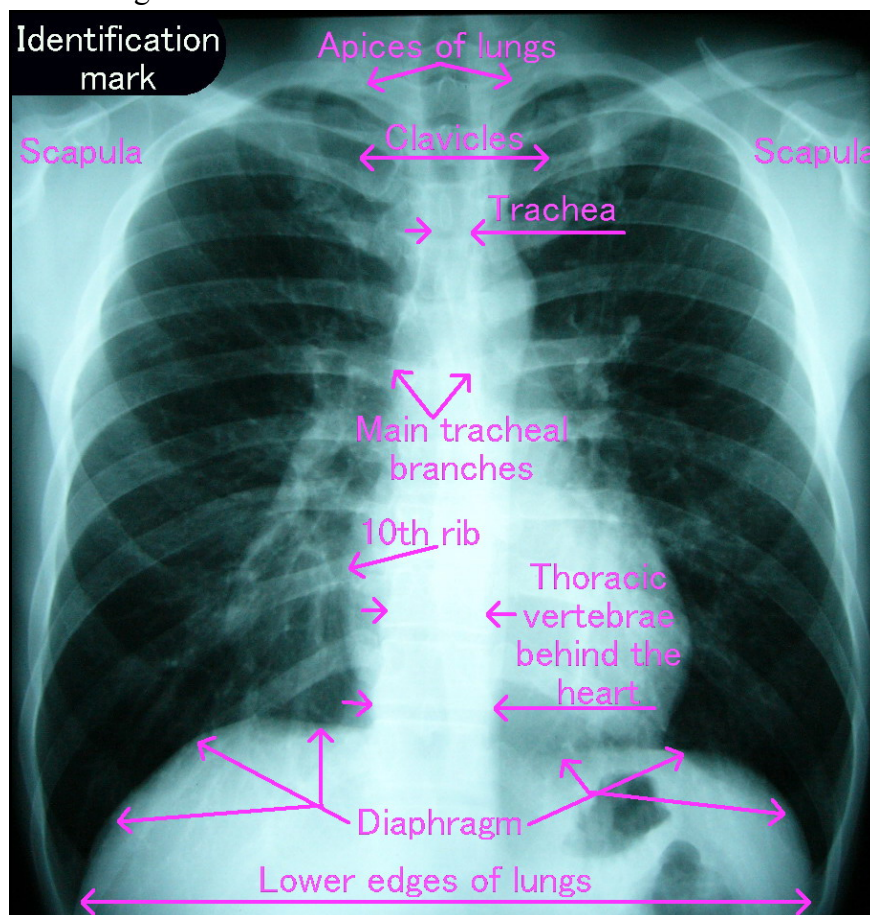
Figure 1.2 Sample chest radiograph taken in the clinic of JATA

Your ability to recognize and assess the quality of chest radiographies should be improved through having the opportunity to carefully and frequently examine the normal appearance of a good quality chest radiograph. By comparing the normal appearance of a good quality chest radiograph with chest radiographs in the field, you can more easily determine if variations in appearance of these chest radiographs represent acceptable or unacceptable quality. Although clinical diagnosis of TB suspects is usually made by chest physicians, TB supervisors also must acquire the fundamental knowledge regarding factors that affect the quality of chest radiographs. This is because TB supervisors can be the key people to suggest the things that radiographers and chest physicians can do to further improve the quality of chest radiographs in their health facilities.

The areas highlighted in this sample chest radiograph indicate the most important points that we have to pay attention to in order to carefully assess the appearance of a chest radiograph. Comparing the appearances of chest radiographs in the field with a standardized good quality chest radiograph in your mind helps you to decide if the quality is acceptable or not. Accordingly, you have to memorize the standard quality of a chest radiograph by carefully and frequently looking at the normal appearance of good quality chest radiographs. The chest radiograph of good quality usually has the following features;

Check points for anatomical positioning and identification of quality chest radiography:

- Complete identification with name of patient, age, name of health facility, and date of examination
- Clear identification mark printed at the place on the upper-left/right side
- No defective lung fields from apices to lower edges
- Whole edges of the both diaphragms traced
- Sufficient inspiration: the posterior 10th rib should be visible above the diaphragm
- Symmetrical location of clavicles and scapulae
- No overlapping of scapulae in the lung fields
- Density of both lung fields visualized symmetrically
- Centrally located trachea and both main tracheal branches visible
- Pulmonary vessels clearly visible in the lung fields and traced to the lung periphery
- Lower vessels in the left lung visible through the heart
- Thoracic vertebrae visible behind the heart
- Artifacts and foreign substances must not be visualized



II. How to take a good quality chest radiography

Fundamentals of X-ray equipment operation

A knowledge of the functions of X-ray equipment is essential to assess the quality of chest X-rays. With respect to the regular maintenance of X-ray equipment, at least one radiographer must be in charge. On the other hand, it is recommended to have a maintenance contract with a local agent for fault detection, calibration and repair work by a qualified X-ray engineer.

The price range for a standard stationary X-ray unit including X-ray generator, X-ray tube and stand, vertical chest stand, bucky table, and control panel starts at approximately USD 30,000. The price for the minimum standard of mobile X-ray unit starts at approximately USD 17,000.

i. Distance between X-ray film and tube focus & X-ray beam alignment

With regard to chest X-ray, the recommended distance between the tube focus and X-ray film (FFD) is in the range of 140-200cm (*Figure 2.1*). Longer distance is more desirable for a radiological chest examination. The main reason for this longer distance is that it improves the image sharpness through geometric means. The X-ray beam must be aligned straight with the X-ray film.

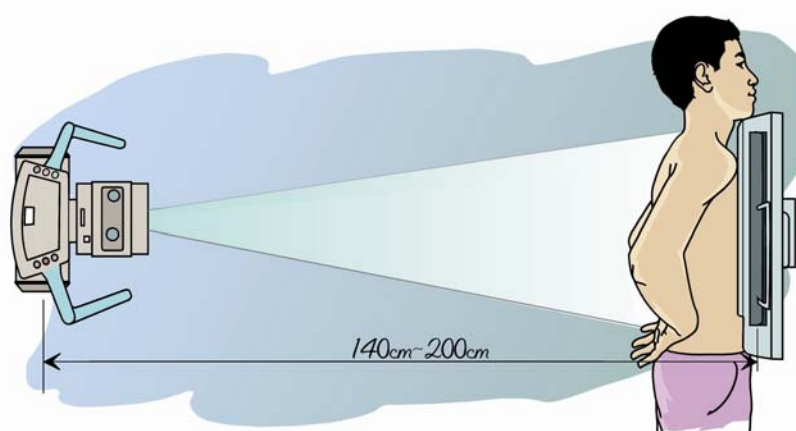


Figure 2.1 Sample illustration for distance between X-ray tube focus and film (FFD)

ii. X-ray tube voltage

The penetrating power of the X-ray beam is controlled by the adjustment of X-ray tube voltage. The higher the voltage setting, the more energetic and penetrative the X-ray that is produced, and the different tissues are visualized at different density levels according to the penetrating power of the X-ray beam. The difference of density levels between the light and dark areas of X-ray film is defined as 'contrast'. In general, the higher the voltage setting, the different organs in the human body are visualized with less contrast in a radiograph.

With regard to the chest radiograph, higher voltage in the range of 100-120kV is recommended; in other words low contrast imaging between lungs and bones is desirable.

Figure 2.2 shows sample X-ray films comparing different contrast imaging of lung and rib bones with low and high X-ray tube voltage. The most important difference caused by X-ray tube voltage is visibility of pulmonary vessels behind the rib bones.

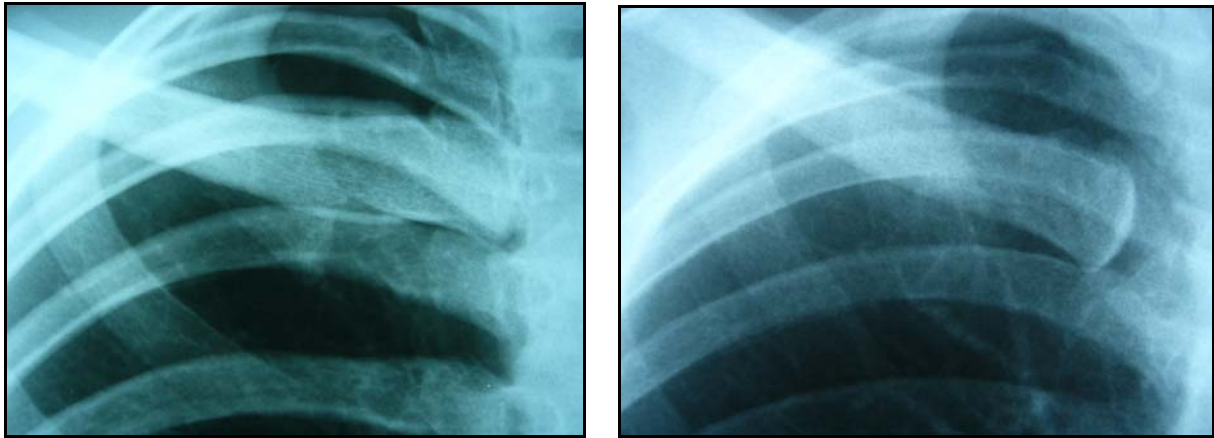


Figure 2.2 Imaging with low X-ray tube voltage (left) and high X-ray tube voltage (right)

The advantage of high X-ray tube voltage is that it produces a more energetic X-ray which penetrates bones so that the pulmonary vessels can be visualized under the bone structure. **Figure 2.3** shows a schematic illustration of the simplified mechanism of difference between high and low tube voltage X-ray. Higher energy X-ray (red lines) penetrates the human body and transfers the information of lung fields to the X-ray film. On the other hand, lower energy X-ray (blue lines) tends to be scattered by the human body and is not able to contribute to the visibility of pulmonary vessels behind the rib bones.

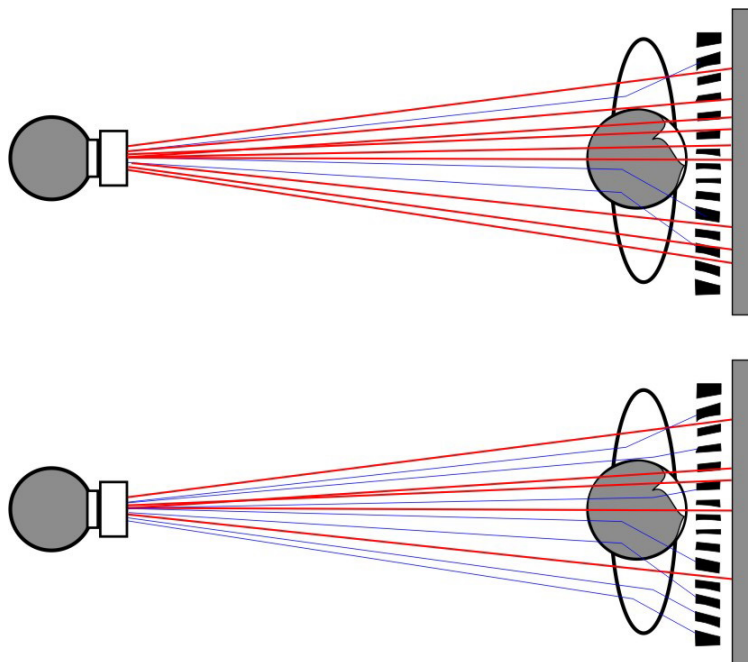


Figure 2.3 Schematic illustration of high (above) and low (below) X-ray tube voltage

iii. X-ray tube current and exposure time

The dosage of the X-ray beam is controlled by 2 functions: X-ray tube current and exposure time adjustment. The higher the current setting and/or the longer the exposure time setting, the more X-ray photons are produced and this affects the higher density of X-ray film. The units of X-ray tube current and exposure time are mA (milliampere) and seconds respectively. In a general way, the dosage of the X-ray beam control is referred to as 'mAs', which refers to the multiplication of mA and seconds. The suitable mAs depends on the X-ray unit used, but the recommended exposure time is less than 0.05 seconds in order to minimize motion artifact caused by the beating of the heart.

iv. Effective focal size of X-ray tube

With respect to the chest radiograph, the recommended effective focal size of the X-ray tube is smaller than 1.2mm. The main advantage of selecting a smaller focal size is that it reduces the blur of the edges of pulmonary vessels in the chest radiograph through geometric means. The degree of appearance of the edge between two density areas in the imaging subject is defined as 'sharpness'. Consequently, a smaller focal size can improve a factor of imaging sharpness. Smaller effective focal size, e.g. 0.6mm, is more desirable for radiological chest examination, however, the smaller the focal size, the harder it is to use a higher mAs setting.

v. X-ray grid

The X-ray grid looks like a flat metallic plate which is the same size as the X-ray film cassette and it contains very narrow lead strips. The function of the grid is to reduce the scattered radiation from the patient and to increase the image sharpness. With regard to the chest radiography with higher voltage techniques (for example, in the range of 80-120kV), the X-ray grid is essential. The minimum required specification of fixed grid for chest radiography is 34 lead strip lines per cm and an 8:1 grid ratio. The appearance of the grid and its schematic illustration of internal structures are shown in *Figure 2.4*.

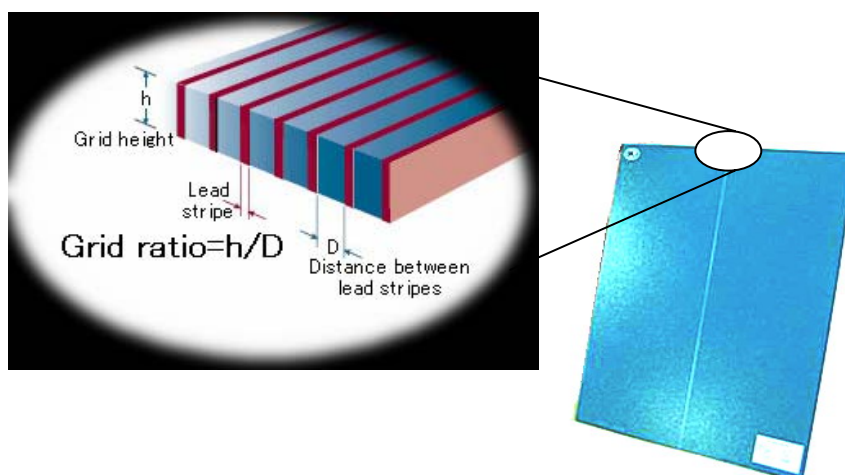


Figure 2.4 Grid and its schematic illustration of internal structures

The higher the specification of the grid, however, the more X-ray exposure will be required. This physical description explains that the higher specification of the X-ray grid needs the larger load capacity of X-ray exposure. The lead strip lines less than 20 per cm must be moved during the X-ray exposure otherwise the lead strip lines are visualized and deleterious to the image quality. The front side of the grid must face the patient and be crossed at right angles to the X-ray beam, otherwise the density of right and left lung fields becomes inappropriately asymmetric as shown in the illustration below (*Figure 2.5*).




Figure 2.5 Bad example showing asymmetric density imaging of lung fields

vi. Electricity power supply for X-ray equipment

Most stationary X-ray equipment needs to be connected to the mains electricity in the range of 100-150A (ampere) with small electrical impedance i.e., 0.3Ω (ohm) or less. The special type of X-ray equipment with high-frequency inverter generator requires only 10-20A electric supply. Most mobile types of X-ray equipment require a 10-20A electric supply. In order to produce a good quality X-ray beam, specifications of the current capacity and its impedance are indicated in the instruction manual specific to that unit of X-ray equipment. The higher the impedance of the electrical supply, the bigger drop of X-ray tube voltage.

vii. X-ray film viewer

Viewing chest radiographs under good viewing conditions is important in order to detect the maximum amount of information. The X-ray film viewer requires a minimum of 2 vertically mounted 15W (Watts) fluorescent tubes and the light intensity of X-ray film should be sufficient and even across the entire surface of it.

viii. Mobile X-ray unit

A mobile X-ray unit is defined as an X-ray unit on wheels, capable of being moved from one location to another. The capacity and stability of X-ray generation by a mobile X-ray unit is limited. Accordingly, mobile X-ray units should be used only for restricted applications. With regard to chest radiography, basically mobile X-ray is not recommended. However, in a place where only a mobile X-ray unit is available, the radiographer can utilize it, paying careful attention to X-ray exposure factors and beam alignment.

Important summary:

- Focus film distance: 140-200cm is recommended
- kV controls image contrast and density: 100-120kV is recommended
- X-ray exposure time: less than 0.05seconds is recommended
- mA controls image density: more than 100mA is recommended
- mAs adjustment: mainly depends on the physical constitution
- Effective focal size: less than 1.2mm is recommended
- Grid improves image sharpness: more than 34 lines per cm is required and less than 20 lines per cm is recommended for moving grid
- Capacity of mains electricity: specifications must be established by the instruction manual of the specific unit of X-ray equipment
- Impedance of mains electricity: less than 0.3Ω is recommended

Regular maintenance:

- Responsibility of the radiographers

Fault detection, calibration and repair work:

- Responsibility of the X-ray engineers of the manufacturer and/or local agent

Fundamentals of screen-film combination system

The intensifying screen is a device made of fluorescent material that emits light when exposed to X-ray. Two types are available. One emits blue light and the other one emits green light. The emitted blue or green light contributes to a blackening effect on the X-ray film. In terms of its blackening function, green light is more effective than blue light so that the rare-earth material (e.g., gadolinium) which emits green light is widely used in recent years. The intensifying screen may be divided into 3 sensitivity categories such as fast, medium, and slow speed. In general, the lower the sensitivity, the more X-ray exposure needed and the better imaging quality produced. With regard to chest radiography, the intensifying screen emits green light and medium speed sensitivity is recommended. *Figure 2.6* shows an illustration of blue and green emission light by different types of intensifying screens exposed to the X-ray beam in a darkroom.

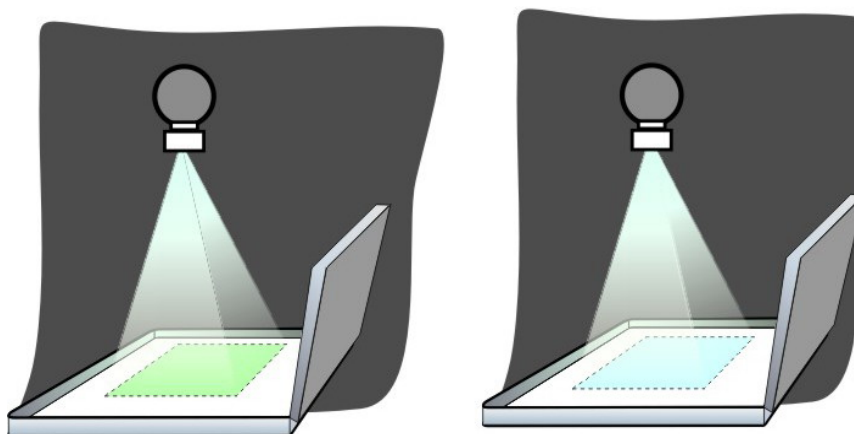


Figure 2.6 Illustration of green (left) and blue (right) emission screens in a darkroom

X-ray film is categorized into 2 types. One is the blue emission light sensitive type and the other one is the green emission light sensitive type. The combination of intensifying screen

and film must be matched according to the type of X-ray film, otherwise the imaging quality will be worsened. **Figure 2.7** shows a sample X-ray film box indicating the type of film it contains. With regard to the chest radiography, ‘general or regular’ of either the blue or green variety is recommended.



Figure 2.7 Sample X-ray film box indicates ‘general purpose’ and ‘green’ type

The stains on the intensifying screen will visualize the artifacts on X-ray film so that the regular cleaning for the intensifying screen is essential. **Figure 2.8** shows the artifacts caused by stains on the intensifying screen.

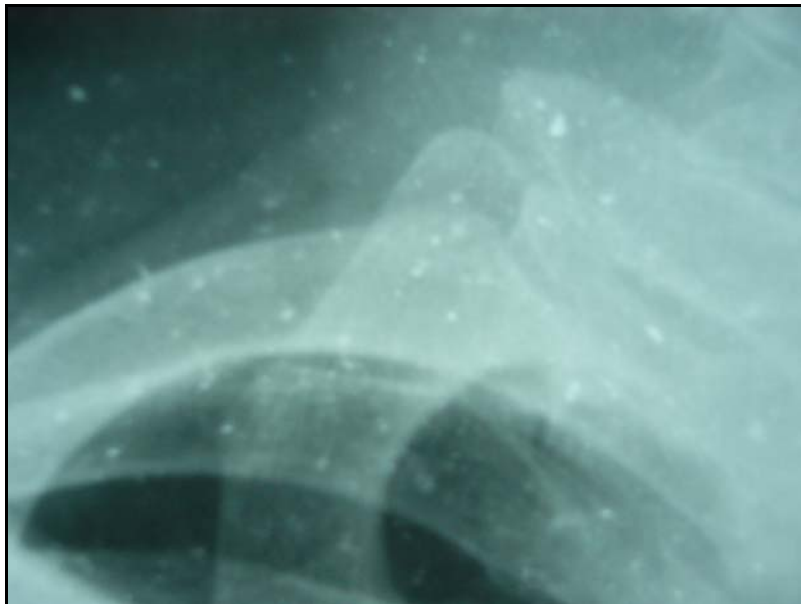


Figure 2.8 Artifact caused by stains on the intensifying screen

Important summary:

- Screen type: green light emission type is recommended
- Screen sensitivity: medium speed is recommended
---e.g., HG-M, XG-S, Lanex Medium, etc
- The type of film must be suitable for the color of light emitted by the screen
- Film type: regular type is recommended
- Screen must always be cleaned through regular maintenance

Fundamentals of darkroom management

Poor darkroom management causes fogging (unwanted density in the areas that are not exposed to the X-ray beam) and artifact (unwanted imaging). For proper darkroom management, you must be careful about the points mentioned below.

With regard to the regular type of X-ray film, the color of safelight is red for both blue and green emission light sensitivity. The recommended electrical power is 15W and should be no more than 25W. The distance between the safelight and the X-ray film should be more than 150cm as shown in the illustration below (*Figure 2.9*).



Figure 2.9 The distance between safelight and developing tank

Each X-ray film has its own expiration date marked on the outside of the film box, and we have to use the film before the expiration date. *Figure 2.10* shows a sample X-ray film box indicating the expiration date of the film it contains.

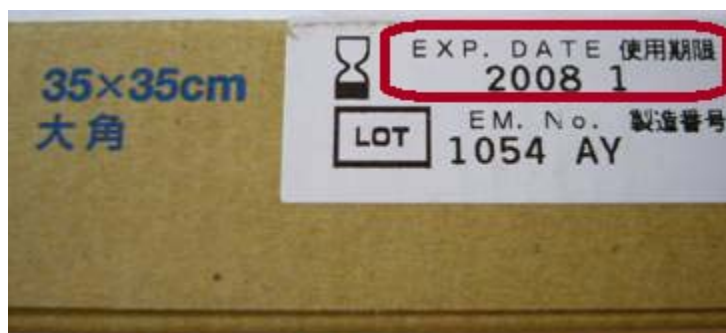

Figure 2.10 Sample X-ray film box showing the expiration date

The temperature and humidity in the darkroom should be controlled through air conditioning and/or a ventilation fan depending on the local circumstances. Temperature of 10-24°C and humidity of 30-50% are recommended as shown in *Figure 2.11*.



Figure 2.11 Sample X-ray film box indicates storage condition

The leakage of light from outside into the dark room must be absolutely avoided by renovation of the darkroom and/or by using some type of lightproof materials. *Figure 2.12* shows 2 examples of X-ray film that show unwanted exposures of light leaking into the darkroom.

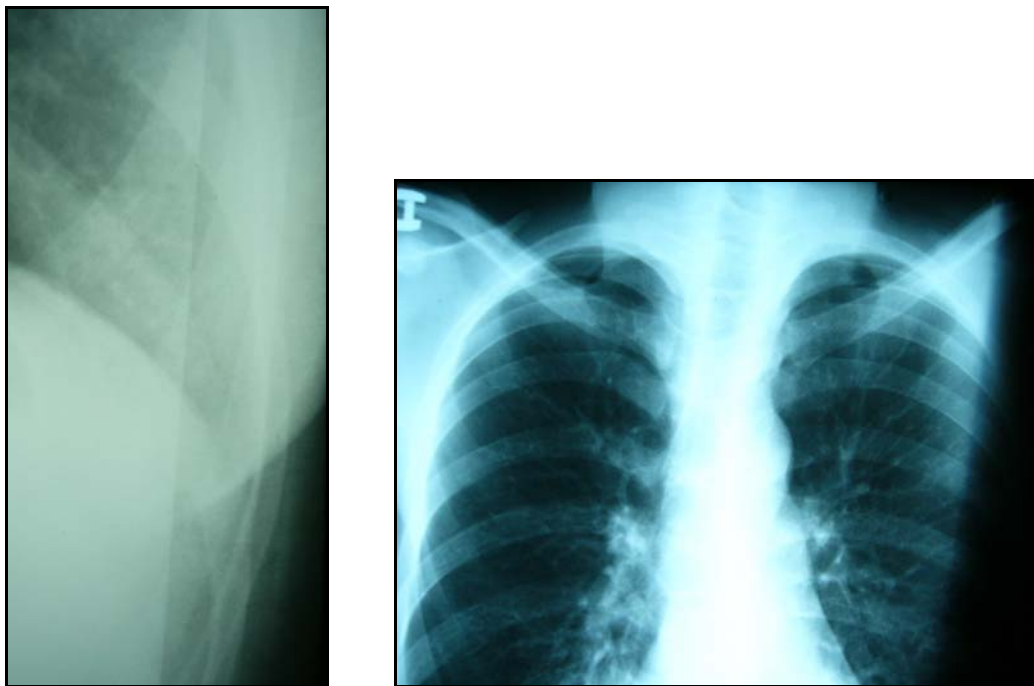


Figure 2.12 Leakage of light into the darkroom causes artifacts on X-ray films

The light from a mobile phone will be another source of light that damages X-ray film in a darkroom as shown in the illustration (*Figure 2.13*).



Figure 2.13

Illustration showing how a mobile phone in the darkroom will damage X-ray films

X-ray film must be handled with care so that it is not bent or touched with dirty fingers in a careless manner. Careless handling of X-ray films causes unwanted types of artifacts on the X-ray films.

Important summary:

Please check

- the expiration date of X-ray film
- the temperature and humidity in the darkroom
- that there is no light leakage in the darkroom
- the color of safelight: RED for regular type X-ray film
- the electric power of the safelight: 15 W is recommended
- that your hands are clean and dry

Fundamentals of X-ray film processing technique

X-ray film processing will be mainly divided into 5 processes: developing, rinsing, fixing, washing, and drying. The implications of these 5 processes for imaging quality are mentioned below. This X-ray film processing can be done by manual procedure or with an automatic processor.

1) Manual processing

i. Developing procedure

The temperature of the developing solution and the developing time are regulated to maintain a consistent density of X-ray film constantly. The higher the temperature and/or the longer the developing time, the darker the density of X-ray film. Exhausted developing solution has less blackening effect and requires a longer developing time which causes excessive fogging at the same time. *Figure 2.14* shows a bad X-ray imaging caused by insufficient stirring of developing solution. Preparation of developing solution should strictly follow the instruction of the manufacturer (*Figure 2.15*).

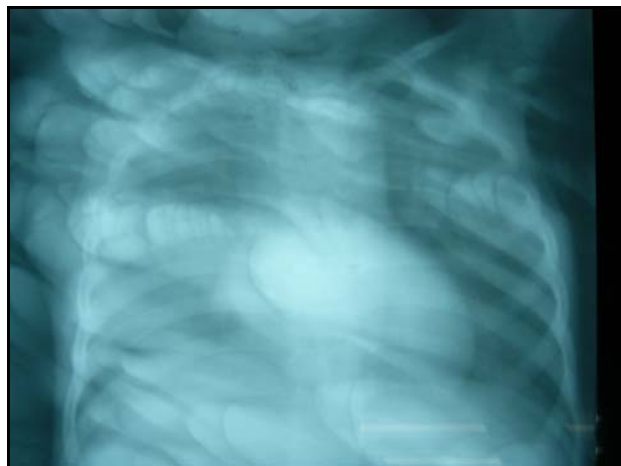


Figure 2.14 Bad X-ray imaging caused by insufficient stirring of developing solution

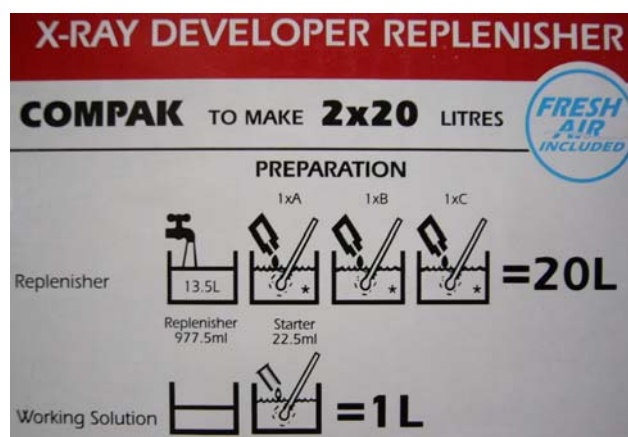

Figure 2.15 Sample instructions for preparation of developing solution

ii. Rinsing procedure

Rinsing is the process of rinsing off the developing solution with water.

iii. Fixing procedure

Fixing is a process that requires at least 5 minutes and fixes the image on X-ray film semi-permanently. Exhausted fixing solution and/or shorter fixing time will cause unwanted stains later on. Preparation of fixing solution should strictly follow the instructions of the manufacture (*Figure 2.16*).

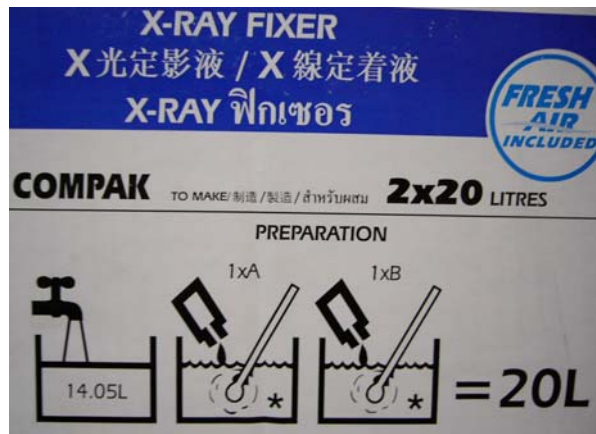

Figure 2.16 Sample instruction for preparation of fixing solution

The condition of developing and fixing solutions can be checked by observation of the color of the solutions. *Figure 2.17* shows two samples of X-ray film processing tanks, indicating good and bad conditions of developing and fixing solutions. Fresh developing and fixing solutions must be made **EVERY MONTH**.




Figure 2.17 Good (left) and bad (right) samples of solutions in the processing tank

iv. Washing procedure

Washing is a process that requires at least 30 minutes to wash out the fixing solution from the X-ray films. Insufficient washing time will cause unwanted yellow color stains later on.

Figure 2.18 is a sample X-ray film that shows yellow color stains caused by improper fixing and/or washing process. The quality of water supply affects the quality of the washing procedure and ultimately the quality of X-ray imaging. Consequently, in order to improve the end quality of the chest radiograph, installation of a filtering device for the water supply for both manual and automatic X-ray film processor is desirable (*Figure 2.19*).

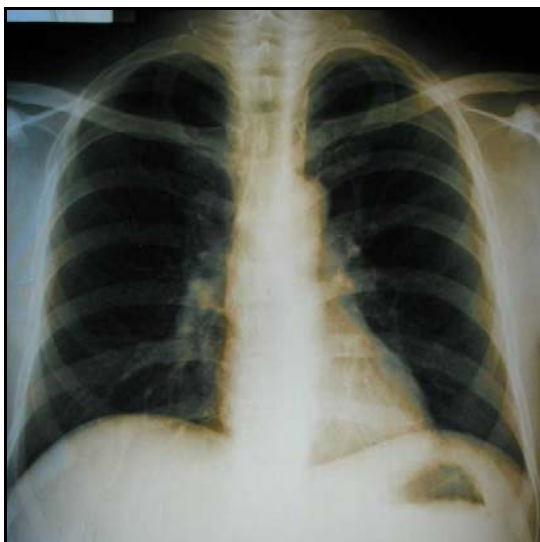


Figure 2.18 Improper processing of X-ray film



Figure 2.19 Filtering device for water supply

v. Drying procedure

Drying is the process that dries out water in a dust free area. The drying temperature must not exceed 35 °C to avoid damage from overheating.

2) Automatic film processor

An automatic X-ray film processor follows the 4 basic procedures as those of manual processing (except rinsing), but under automated and controlled conditions. Consequently, the imaging quality of X-ray film is constant and better and the processing duration is shorter than with manual processing.

On the other hand, the operation of an automatic X-ray film processor requires appropriate and regular maintenance, a stable power supply, an adequate water supply for washing the film and the regular purchase of developing and fixing solutions.

The temperature setting of the developing solution and the drying procedure must be done following the instructions. With respect to the regular maintenance of the automatic X-ray film processor, at least one radiographer must be in charge of this task. Regarding fault detection and repair work, it is recommended to make a maintenance contract with a local agent.

For protection against an unreliable supply of electricity, the equipment should be plugged into a voltage stabilizer and also wired to the electric generator so that it will have a power supply in the event of frequent black outs.

The price for a compact size automatic X-ray film processor ranges from USD 3,500 to USD 6,500. The price of an automatic X-ray film processor mainly depends on the X-ray film processing capacity per hour.

Lastly, some references for further reading are listed in Annex 1, in order to improve your understanding of the details with respect to the areas of clinical, technical and quality assessment of chest X-ray.

Important summary:

- Developing procedure:
 - higher the temperature → darker the density
 - longer the time → darker the density
 - exhausted solution → less dark the density
- Fixing procedure:
 - at least 5 minutes needed
- Washing procedure:
 - at least 30 minutes needed
- Drying procedure:
 - no more than 35 °C
- Automatic X-ray film processor
 - The temperature for developing solution, developing time, and temperature for drying procedure must be set following the instructions
 - A constant supply of water and electricity are needed
 - Regular maintenance is even more important than in manual processing
 - Maintenance support from a local agent is required

Specifications of X-ray equipment for chest radiography

There are three important issues which must be considered for the purchase of X-ray equipment and its accessories. Firstly, the quality standards of X-ray equipment and its accessories is an important benchmark as the selection criterion. The International Organization for Standardization (ISO) has regulatory standards for medical equipment.

ISO13485:2003 specifies the requirements for a quality management system where an organization needs to demonstrate its ability to provide medical devices and related services that consistently meet customer requirements and regulatory requirements applicable to medical devices and related services. Secondly, the cost and quality of installation, user training and maintenance support by the X-ray engineers from the manufacturer and/or local agents are also important factors as selection criteria. Lastly, the warranty period and maintenance contract of the X-ray equipment must be considered.

A detailed consumer guide for the purchase of X-ray equipment is located under the reference number 10 in Annex 1. In this section, an example of minimum essentials for appropriate specifications of X-ray equipment and other items are described as follows;

i. X-ray equipment

- 1) **X-ray generator and X-ray tube:** Regarding the high tension generator, a high-frequency inverter system is recommended. With respect to the X-ray tube, a rotating anode with less than 1.2mm effective focal size is recommended. The standard X-ray exposure factors for chest radiography is considered to be around 100-120kV with 100-200mA for a duration of 0.01-0.05seconds. Accordingly, the minimum required capacity of an X-ray generator and X-ray tube in small size hospitals is capable of producing 120kV at 100mA for an exposure duration of 1 second (100mAs) and for referral hospitals it is 120kV at 200mA for an exposure duration of 1 second (200mAs).

The mobile type of X-ray unit is not recommended for the chest radiography except for bedridden inpatients.

- 2) **X-ray grid:** The minimum required quality of fixed grid is more than 34 lead strip lines per cm with 8:1 grid ratio and 120cm focus distance. The X-ray grid in which the lead strip lines contain less than 20 lines per cm must be assembled together with a moving mechanism (*see Figure 2.4*).

ii. Electric supply for X-ray equipment

The minimum required electric supply for the standard type of X-ray equipment is 100-150A. The recent technology of X-ray equipment with high frequency inverter generator accepts 10-20A electric supply in much the same way as a home appliance. The impedance of the mains electricity cable to the X-ray equipment must be 0.3Ω or less otherwise high impedance may cause the voltage drop during X-ray exposures.

iii. Screen-film system

Green emission with medium speed type of screen is recommended for chest radiography, e.g. HG-M, XG-S, Lanex Medium, etc.

iv. Automatic film processor

The use of automatic film processor is recommended for the health facility which may take X-rays at a rate of more than 10 patients per hour, otherwise manual film processing is more appropriate in order to consume less of the developing solutions. The minimum processing capacity of a small size of automatic film processor can be available from 45 X-ray films (35cm x 43cm) per hour.

Fundamentals of digital X-ray imaging system

Instead of the conventional screen-film diagnostic X-ray system, the digital X-ray imaging system composed of electronic flat-panel X-ray detector, high resolution grayscale diagnostic display, and high performance computer, is now being marketed. This is a product brought about by a technological revolution in the radiological technology field. The initial investment in a digital X-ray imaging system and the maintenance expenses are still costly and technical supports are insufficient in most developing countries under the present circumstances. And we still need qualified radiographers for its appropriate operation and experienced physicians for diagnosis of the digital imaging of chest radiographies. On the other hand, the adoption of a digital X-ray imaging system is considered a solution for improving the quality of chest radiography.

Consequently, under the present situation, the digital X-ray imaging system is not the first priority for the developing world. Nevertheless, the diffusion of this technological revolution is certainly expanding steadily just like the internet and mobile phones so that the digital X-ray system also may be rapidly introduced to the developing world due to its quality and convenience. Therefore, the key components of the digital radiography system are described in this section.

i. X-ray detector technology

Many different types of digital detectors of X-ray are now being marketed. There may be a tendency to think of these devices as equivalent and interchangeable because of their similarity in appearance. However, the methods of image capture used in digital detectors are categorized into two distinct types of technology: computed radiography (CR) and digital radiography (DR).

CR is the technology which is dependent on the use of phosphor-based plates which are processed in much the same way as X-ray film with cassettes. The X-ray imaging data of the phosphor based plates is decoded with a laser detector into electric signals.

DR technology can be categorized by two different mechanisms: such as indirect and direct digital detector technologies. An indirect digital detector uses a two-step process for

producing the electric signals. The first step requires a scintillator, such as cesium iodide doped with thallium [CsI(Tl)] to capture the X-ray and convert it to light. The second step is to produce the electric signals with photodiodes converted from the light. A direct digital detector generates the electric signals from the X-ray with a photoconductor, such as amorphous selenium (a-Se) and silicon (a-Si).

ii. Characterizing parameters of detector performance

There are three important imaging quality parameters, density, contrast and sharpness that measure the X-ray detector technology. Grayscale is a measure of dynamic range which quantifies image density. Detective quantum efficiency (DQE) is a measure of signal-to-noise ratio which quantifies image contrast. Modulation transfer function (MTF) is a measure of spatial resolution which quantifies image sharpness.

iii. Rejection of scattered radiation technology

Digital detectors are subject to the same deleterious effects on image contrast by scattered radiation as conventional screen-film systems. Instead of moving the X-ray grid to remove lead strip lines from the radiographic images, several digital radiography detectors use an alternative approach of using grids with very high densities, more than 78 lead strip lines per cm.

iv. Picture archiving and communication system (PACS)

The imaging data of digital radiography can be sent to display monitors, high-definition laser printers, and archiving and communication system. The full benefit of the digital radiography system can be achieved by using the PACS with a high performance computer system.

v. Diagnostic display

Initially, the hard copy of the digital radiographic image is viewed on an X-ray viewer in the same way as the conventional screen-film system. The recent technology on flat panel display is now being marketed, with a high resolution grayscale display which meets the specifications for radiological diagnosis.

vi. Specifications of digital X-ray imaging system

- 1) **X-ray generator and X-ray tube:** The recommended specifications for the X-ray generator and the X-ray tube are the same as for the conventional X-ray imaging system.
- 2) **X-ray grid:** For digital radiography, a finer and lower grid ratio is recommended, compared to the conventional radiography system (i.e. more than 60 lines per cm with a 4:1 grid ratio).

- 3) X-ray detector:** The performance of a direct digital detector is better with respect to DQE and MTF than an indirect digital detector or CR. The material (e.g., CsI(Tl) or a-Se), mechanism (e.g., direct or indirect) and pixel size (e.g., 100-200 μ m) of the detector are the key factors affecting the image quality and the value for price.
- 4) Computer software:** The digital radiography must have appropriate PACS and sufficient processing capacity for the needs of a particular health facility.
- 5) Diagnostic display:** Grayscale contrast range (e.g., 256, 1024, 3061 and 4096), spatial resolution (e.g., 1600dotsx1200lines, 2048dotsx1536lines, 2560dotsx2048lines), and brightness are the main quality factors for the diagnostic display. The capacity of data processing is another factor and it depends on the display memory.

vii. Advantages of digital X-ray imaging system

- Digital imaging can achieve higher spatial and contrast resolution and dose efficiency.
- Digital images can be adjusted electronically at a workstation to optimize the quality of X-ray of the desired anatomy.
- Digital radiography can achieve rapid processing and fewer repeat examinations by digital processing technology. And it can increase room use and reduce the cost through curtailment of darkroom and film processing procedures.
- Digital radiography system can efficiently archive and retrieve massive amounts of imaging data.
- Digital imaging data can be transmitted onto a workstation monitor and printed on film, as well as for electronic storage.
- Digital images can be sent by electronic media such as email or mobile phones, to a remote reader for diagnosis.

Summary of advantages of digital X-ray imaging system:

- Feasible imaging quality can be adjusted by computer processing
- This allows for easy and quick image processing
- X-ray images are presented on a diagnostic display (X-ray film and its processing procedures in a dark room are not needed)

Summary of disadvantages of digital X-ray imaging system:

- Costly initial investment:
Prices range from USD 61,000 for a retrofit type of CR system without X-ray equipment to more than USD 400,000 for an entire unit of digital X-ray imaging system
- Advanced maintenance technology and costly running expenses
- Vulnerable to unreliable electric power supply

III. How to assess the quality of chest radiography

The method for assessment of the quality of chest radiography described here is one which is modified for resource constrained settings by simplifying the JATA model. The simplified assessment method does not need special electrical devices except for film viewer(s), but assessors, usually TB supervisors, need to be trained so that they can understand the contents of this handbook and to gain experience in assessing the quality through practice. In this chapter, we begin with an overview on how to use the assessment sheet on page 29, followed by explaining more details about the procedures and factors necessary for assessment. As the ‘six factors’: Identification marking of the patient, Patient positioning, Density, Contrast, Sharpness, and Artifacts are explained later, you should refer to ‘Simple Assessment Procedures of the Quality of Chest Radiograph’ from page 30 to 60. The assessment sheet and the summary of the simple assessment procedures are listed in Annex 2.

Of the six factors used for assessment, the four factors (density, contrast, sharpness, and artifacts) are mainly dependent upon the specification of X-ray equipment, the combination of intensifying screen and film, X-ray exposure factors, and X-ray film processing procedure. They seriously affect the quality of chest radiographic imaging. In order to assess the quality of chest radiography, it may not be essential for TB supervisors to master radiological skills, but it is necessary both to understand the fundamental idea of the four factors and to view a substantial number of good samples of chest radiographs carefully.

In order to examine not just the quality of each chest radiograph but the comprehensive quality as a facility equipped with X-ray equipment, JATA empirically recommends that the three representative films which radiographers or physicians regard as high quality should be selected from routinely taken chest radiographs in a given period. This method is based on the viewpoint that the quality of chest radiographs is more likely to be affected by a series of various procedures such as patient positioning, X-ray exposure and film developing, and X-ray equipment itself rather than by chance. It seems to be almost independent to accidental events whether they can take high quality radiographs or not, because other chest radiographs taken at the same facility are also highly assessed as whole. Unless they pay special attention to each procedure from positioning to film development and have a good eye for quality, they will fail in taking high quality radiographs. Therefore, it is not too much to say that high quality chest radiographs can be produced through a good eye for quality which radiographers or physicians can develop through the guidelines described in this handbook.

How to use the assessment sheet

TB supervisors can easily assess the quality of chest radiography at a health facility by using the assessment sheet according to the procedures mentioned in this section.

Preparation (Figure 3.1)

- 1) A model chest radiograph which has been chosen by authorities
- 2) Film viewer(s)
- 3) Some copies of the assessment sheet and pens or pencils
- 4) This Handbook

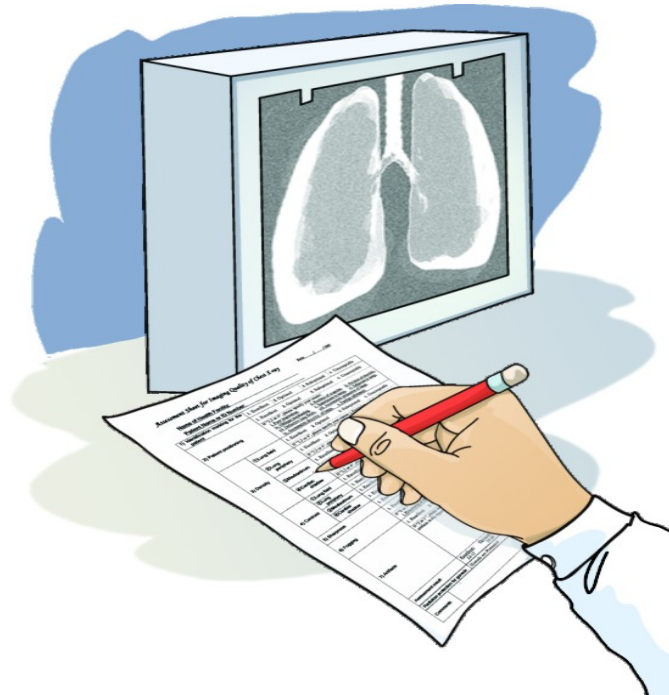


Figure 3.1 Assessment sheet and X-ray film viewer

Participants

Three sorts of technical staff are the most preferable: TB supervisors and physician(s) who usually interpret chest radiographs, radiographer(s) who are actually engaged in exposure and film development, and others.

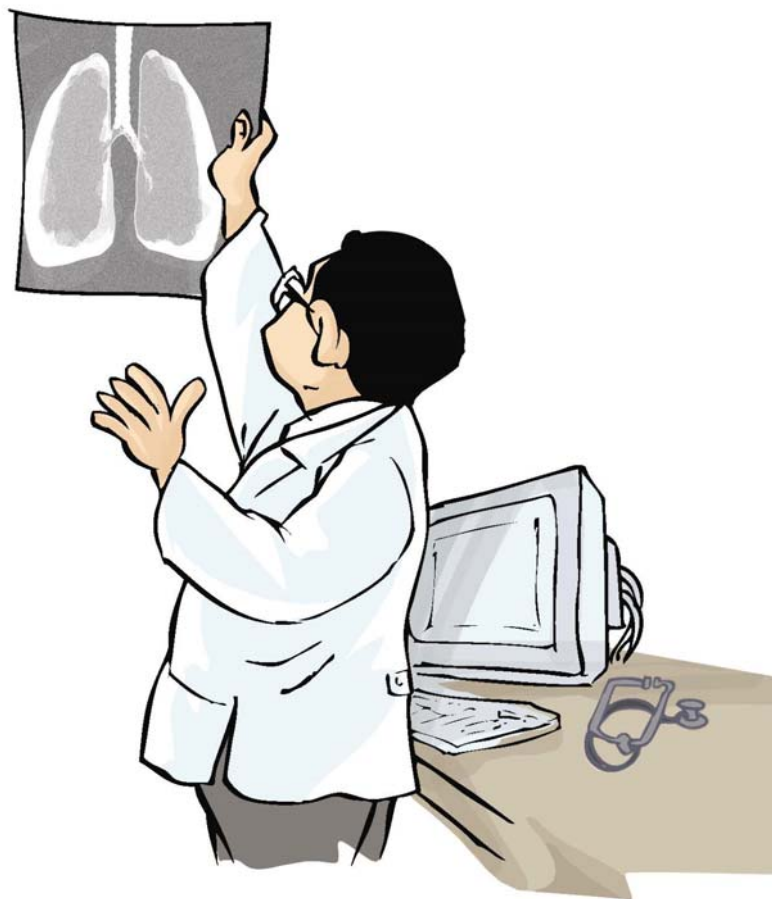The assessment sheet covers the following 6 factors:

- 1) Identification marking of the patient (see page 30)
- 2) Patient positioning (see page 32)
- 3) Density (see page 44)
- 4) Contrast (see page 47)
- 5) Sharpness (see page 53)
- 6) Artifacts (see page 55)

You should start the assessment with ‘Identification marking of the patient’ on the assessment sheet, and proceed one by one to the ‘Artifacts’ according to the procedures. In addition to these 6 factors, ‘Radiation protection for the gonads’ is included. This factor is not directly related to the quality of chest radiography, but it is important to avoid unnecessary exposure to the patients.

Each factor is to be scored using the following scoring system: 1=“Good/None”, 2=“Fair/Slight”, and 3=“Poor/Present”, and the overall assessment result can be decided by the total score for the 6 factors (see page 59) .

If you find any problematic factors, you should take some actions to improve the quality of chest radiography. The suggestions are provided in the red lined square under ‘Suggested actions for improvement’. In addition, you can refer to some textbooks listed in Annex 1 for further understanding of the problems or solutions.

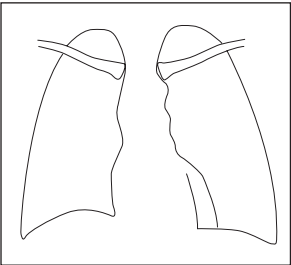


Do not do Quality Assessment in this way

Name of Health Facility:

Date when film was taken / /

Patient Name or ID Number:

1) Identification marking of the patient		1. Good	2. Fair	3. Poor
2) Patient positioning “Good ” is the score of 0 or 1 excluding items i. or ii. “Fair” is neither “Good” nor “Poor”. “Poor” is a score of 5 or more, or any score with both i. and ii.		Please check the following 7 items: i. Defective lung fields <input type="checkbox"/> Yes or <input type="checkbox"/> No ii. Poor inspiration <input type="checkbox"/> Yes or <input type="checkbox"/> No iii. Oblique positioning <input type="checkbox"/> Yes or <input type="checkbox"/> No iv. Position of clavicles <input type="checkbox"/> Yes or <input type="checkbox"/> No v. Position of scapulas <input type="checkbox"/> Yes or <input type="checkbox"/> No vi. Asymmetric density of lungs <input type="checkbox"/> Yes or <input type="checkbox"/> No vii. Foreign substances <input type="checkbox"/> Yes or <input type="checkbox"/> No		
		1. Good	2. Fair	3. Poor
3) Density sub-total score 1. Good (4-5) 2. Fair (6-9) 3. Poor (10-12)	① Lung field	1. good	2. fair	3. poor
		If “2 or 3”, please specify your reason: i. Excessive, ii. Insufficient		
	② Lung periphery	1. good	2. fair	3. poor
		If “2 or 3”, please specify your reason: i. Excessive, ii. Insufficient		
	③ Mediastinum	1. good	2. fair	3. poor
	If “2 or 3”, please specify your reason: i. Excessive, ii. Insufficient			
	④ Cardiac shadow	1. good	2. fair	3. poor
	If “2 or 3”, please specify your reason: i. Excessive, ii. Insufficient			
4) Contrast sub-total score 1. Good (4-5) 2. Fair (6-9) 3. Poor (10-12)	① Lung field	1. good	2. fair	3. poor
	② Lung periphery	1. good	2. fair	3. poor
	③ Mediastinum	1. good	2. fair	3. poor
	④ Cardiac shadow	1. good	2. fair	3. poor
5) Sharpness		1. Good	2. Fair	3. Poor
6) Artifacts <div style="border: 1px solid black; padding: 5px; display: inline-block;"> 1. None 2. Slight 3. Present </div>	If “2 or 3 ”, please indicate the place of artifacts in this figure:			
<div style="border: 1px solid black; padding: 10px; text-align: center;"> Assessment Result: Total score for the 6 factors is _____ (6 – 18) </div>				
<div style="display: flex; justify-content: space-between;"> <div> Excellent: 6 or 7 , Fair: 8-13 with 2 “Poor/Present”s or less </div> <div> Good: 8-11 without any “Poor/Present” Poor: 14-18 or with 3 “Poor/Present”s or more </div> </div>				
Radiation protection for the gonads		Gonads are Protected Gonads are NOT protected		
Comments				Assessor

Simple assessment procedures of the quality of chest radiography

The six most important factors of assessment procedures are highlighted in this section. The factors presented here are the minimum required for overall quality assessment of chest radiography, so you have to carefully follow the steps as mentioned below.

1) Identification marking of the patient

- “Good” example includes all the four identifications (name of patient, age, name of health facility, and date of examination) outside the lung fields.
- “Fair” example is missing 1 or 2 identifications of the four outside the lung fields.
- “Poor” example has no information and/or marking material placed in the lung fields.

Whenever the radiological examinations are carried out, the radiographers must be sure to make an identification mark on the X-ray film, identifying that film with that particular patient. All the four identifications, marking of the name of the patient, the patient’s age, the name of the health facility, and the date of the examination, must be clearly marked on the X-ray film.

This is an essential and primary duty for radiographers for avoiding mismanagement of the radiographs. Although there are several ways to print the patient identification on the X-ray films, marking with an identification device and/or alphabetic metallic marks is the most preferable. *Figure 3.2 - Figure 3.4* show some examples of identification marking for the patients.

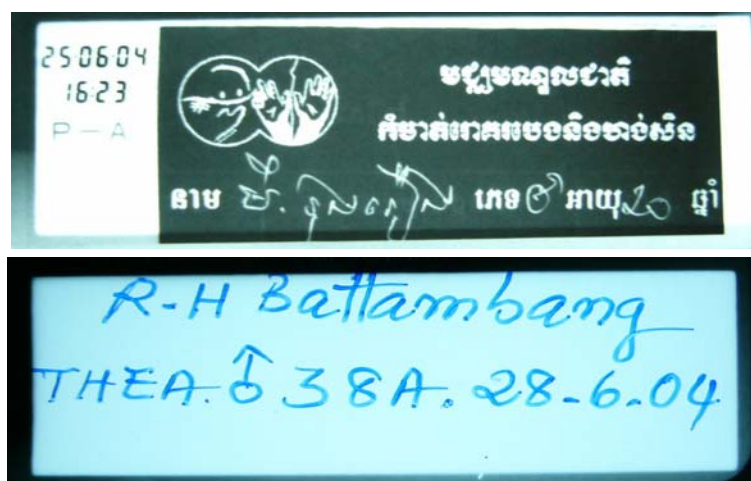


Figure 3.2 “Good” examples of marking by device (above) and by hand writing (below)

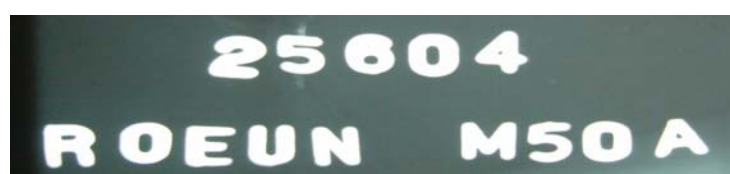

Figure 3.3 “Fair” example of identification: There is no health facility name

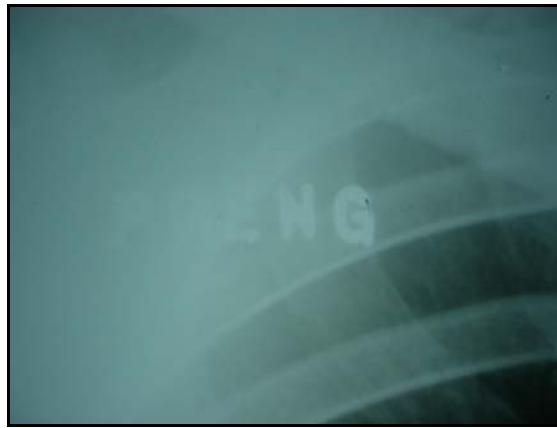


Figure 3.4 “Poor” example of identification: Marking is inside of the lung field

Identification is better done before processing of X-ray films. This is simply essential to avoid misidentification by radiographers when there are 2 or more X-ray examinations of different patients done at the same time. Accordingly, an identification device and/or alphabetic metallic marks for X-ray examination must be prepared together with the X-ray equipment. If radiographers are marking the identifications by hand writing after processing of the X-ray film, identification of the patient must be carefully done to avoid misidentification.

Figure 3.5 shows an X-ray cassette specially designed for an identification printing device and a simple type of identification printing device.



Figure 3.5 Special X-ray cassette (left) and simple identification printing device (right)

Your finding:

The X-ray films are not marked clearly with the name of the patient, the patient's age, the name of the health facility, and the date of the examination.

Suggested actions for improvement:

- Ask radiographers about: availability of patient name printing device
- Ask radiographers about: availability of metallic marks
- Better to avoid hand writing the identifications after the processing

2) Patient positioning

Patient positioning is checked in terms of the following 7 items:

- i. Defective lung fields
- ii. Poor inspiration
- iii. Oblique positioning
- iv. Position of clavicles
- v. Position of scapulas
- vi. Asymmetric density of lungs
- vii. Foreign substances

Among the seven, the first 2 items, Defective lung fields and Poor inspiration, are given higher priority due to their significance. If either of the two is observed, you should score it as “Fair” at best. If both of the two are observed, you should score it as “Poor” regardless of the results of the other five items.

- “Good”: the number of problems excluding defective lung fields or poor inspiration is 0 or 1.
- “Fair”: neither “Good” nor “Poor”.
- “Poor”: the number of problems you observed is 5 or more, or with both defective lung fields and poor inspiration.

The gold standard for the positioning of a general chest radiography is ‘Erect’ meaning the patient is standing, and the X-ray beam direction is ‘Posterior-Anterior: PA’ meaning back to front. The recommended positioning of chest radiography is always PA even for children and patients who are sitting on a stool because they are unable to stand.

Figure 3.6 and 3.7 show an illustration of standing and sitting positioning examples for chest X-ray. The main reason that the PA technique is used for chest radiography is to avoid the magnified imaging of the heart and clavicles on the chest radiograph due to the geometrical factors related to the distance of the X-ray tube and film, in which case interpretation of mediastinal structure and apices of the lungs is more difficult. If you are not familiar with interpretation of chest radiographs, simply understand that the gold standard for the positioning for chest radiography is the PA technique.

Important summary:

- Bad positioning creates unacceptable quality of chest radiographs
- Positioning is completely the responsibility of the radiographers, not the responsibility of the patients

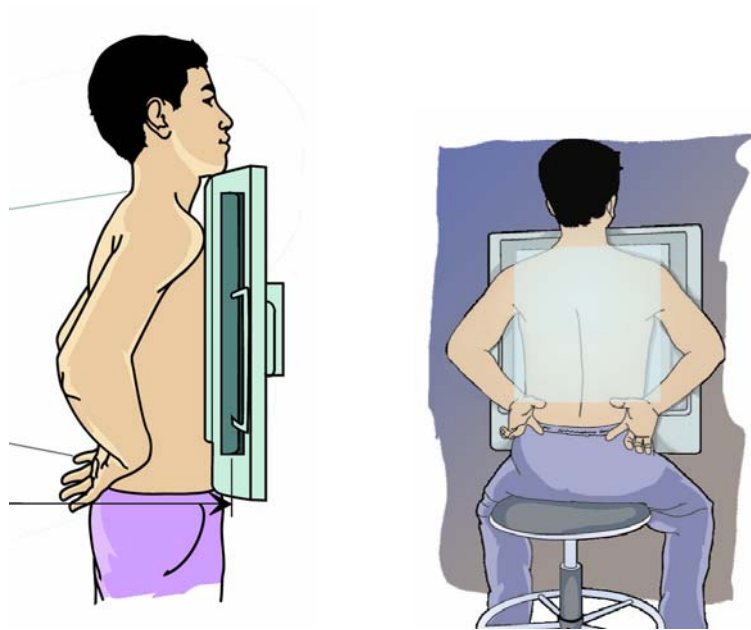


Figure 3.6

Excellent example for standing (left) and sitting positioning (right) of chest radiography

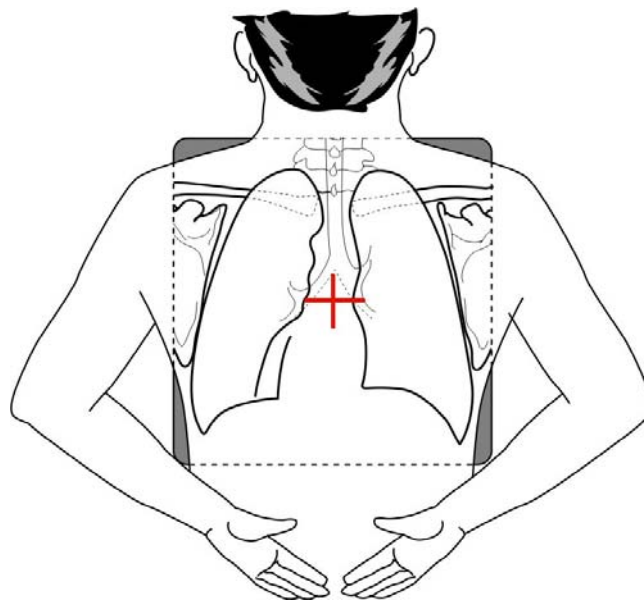


Figure 3.7

Chest radiography by the PA technique: red lines show the center of the X-ray beam

i. Defective lung fields

- If you observe that any defective part of the lung fields, even a small portion, exist in the X-ray film when you put the chest radiograph on a film viewer, you should tick YES for “Defective lung fields”.

The entire lung fields of the patient must be well imaged on the X-ray film, without a defective imaging of any section of the lungs. **Figure 3.8** shows schematic illustrations of ideal imaging and also a bad example of defective lung fields by unacceptable preparation of

the patients. **Figure 3.9** shows the defective lung fields caused by light leakage in a darkroom. The defective part of the chest radiograph will be checked on the X-ray film viewer.

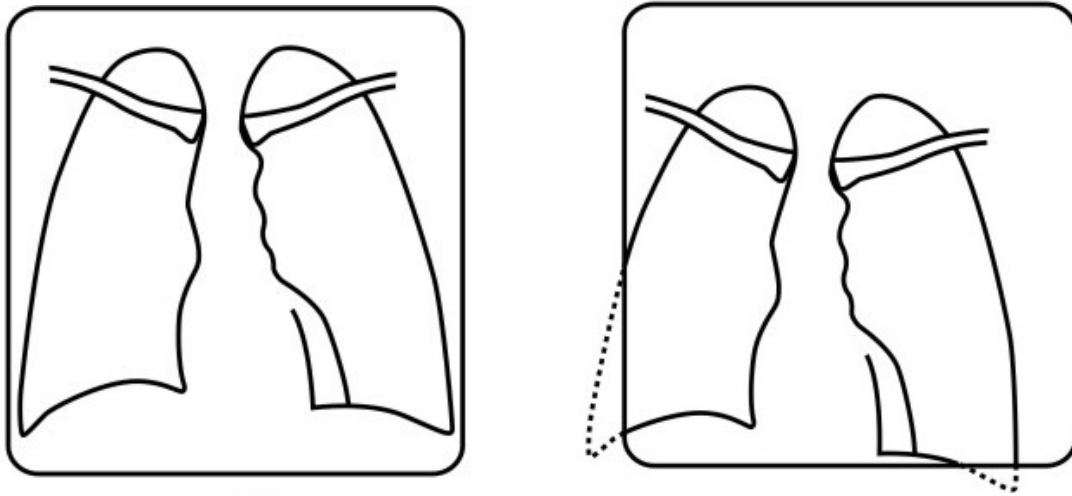


Figure 3.8 Ideal position of lungs (left) and bad example of defective lung fields (right)

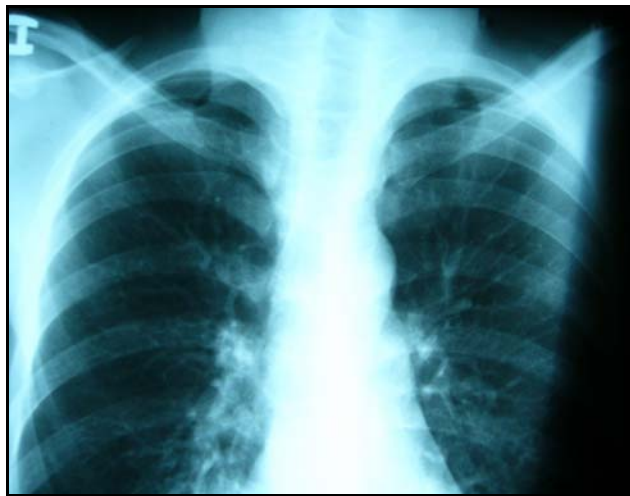


Figure 3.9 Defective lung field due to light having leaked into the darkroom

Your finding:

The entire lungs are not visualized in the X-ray film.

Suggested actions for improvement:

Please ask radiographers about

- the location of the cassette
- the patient positioning
- Light/X-ray beam alignment test

ii. Poor inspiration

- If you find all of the lower line of the 10th rib (usually of the right lung) seen below the line of the right diaphragm, you should tick YES for “Poor inspiration”.

The patients must fully understand the meaning of holding a deep breath during X-ray exposure. Proper understanding of the procedure for chest radiography by the patients achieves the cooperation of patients, which is one of most critical factors for producing good quality chest radiography.

Radiographers must sincerely explain and convince the patients who do not know the meaning of holding a deep breath. To make sure the patients know how to take and hold a deep breath, radiographers should provide the instruction before X-ray exposure. **Figure 3.10** shows an example from the same patient, displaying excellent and poor inspiration during X-ray exposure.

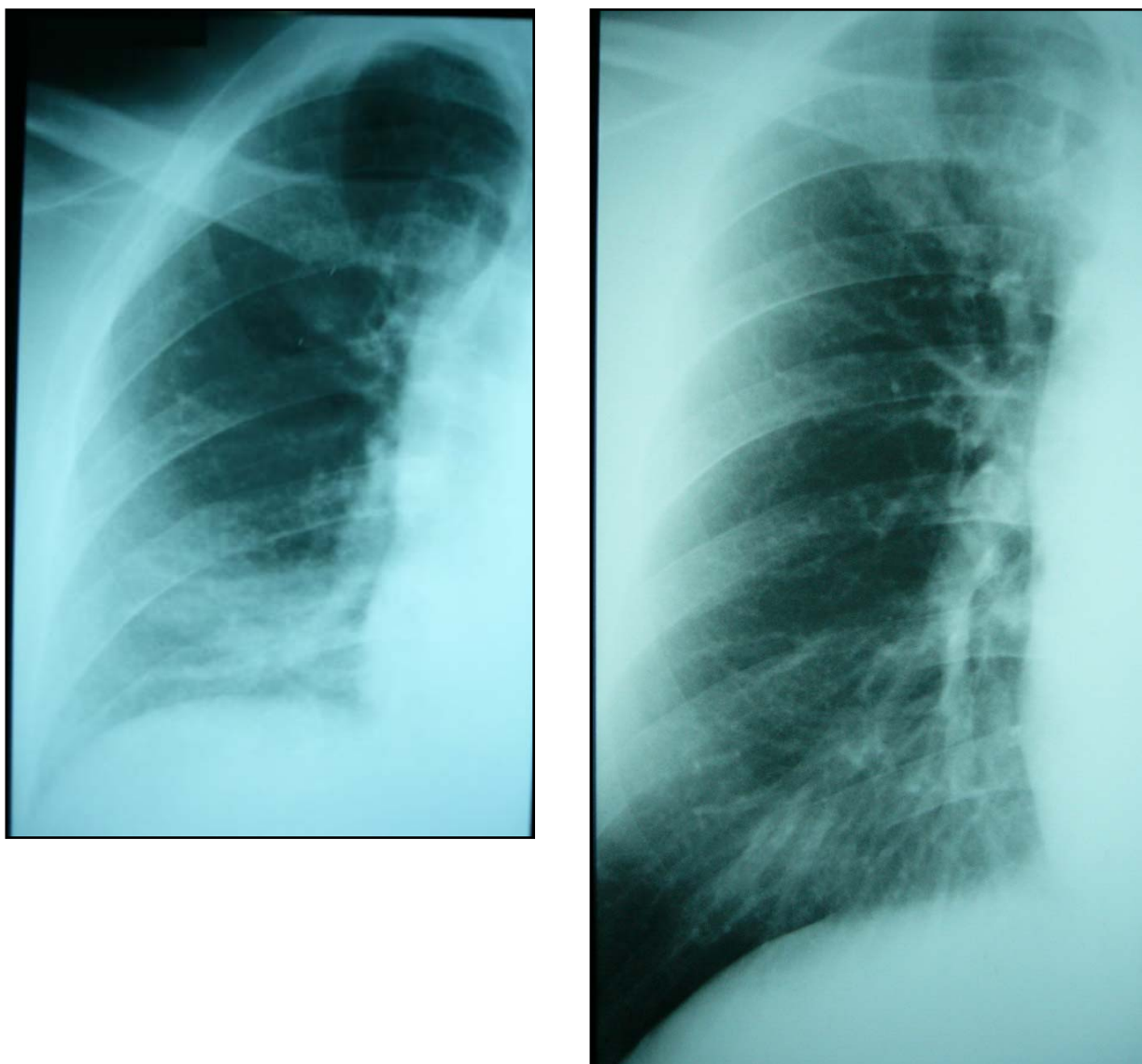


Figure 3.10 Insufficient (left) and good (right) inspiration taken with the same patient

At least some part of the lower line of 10th posterior rib bone should be seen above the line of the right diaphragm by full inspiration. **Figure 3.11** shows schematic illustrations of “Poor” and “Good” inspiration of lung fields on the chest radiographs. The posterior part of 10th rib bone is painted as black in this Figure 3.11.

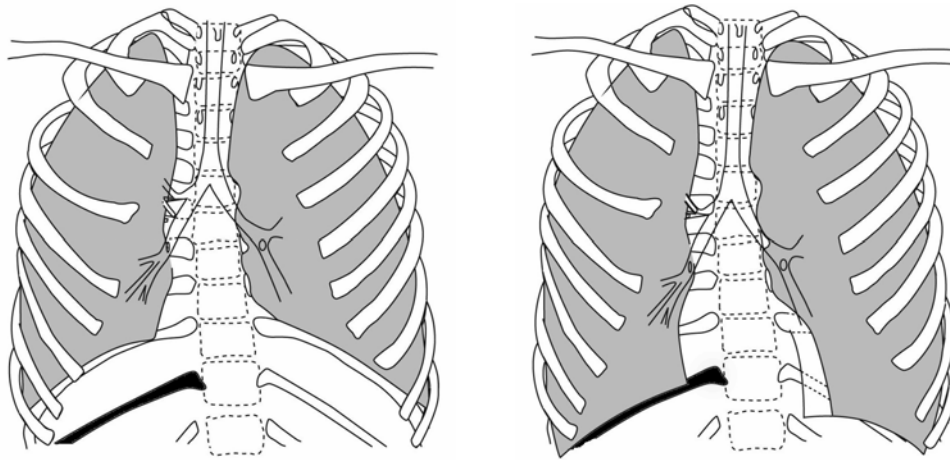


Figure 3.11 Schematic illustrations of bad (left) and good (right) inspiration

Your finding:

Poor inspiration of air on the chest radiograph

Suggested actions for improvement:

- Ask radiographers: how they ensure that the patients hold a deep breath
- Ideal inspiration level of air for chest radiograph
 - Right lung: the line of the 10th rib bone
 - Left lung: lower than the right lung

iii. Oblique positioning

- If you observe that the sterno-clavicular joints are asymmetrically placed and the differences of more than 5mm between the right and the left, namely, the difference in the distances from the right or the left clavicles to the spinous process of thoracic vertebrae is more than 5mm, you should tick YES for “Oblique positioning”.

With regard to the positioning of the patient for PA technique, it is essential that 3 things be well aligned: the patient, the X-ray cassette and the X-ray beam. **Figure 3.12** shows an illustration of an ideal alignment and **Figure 3.13** shows 2 examples of unacceptable alignment.




Figure 3.12 Illustration of ideal alignment

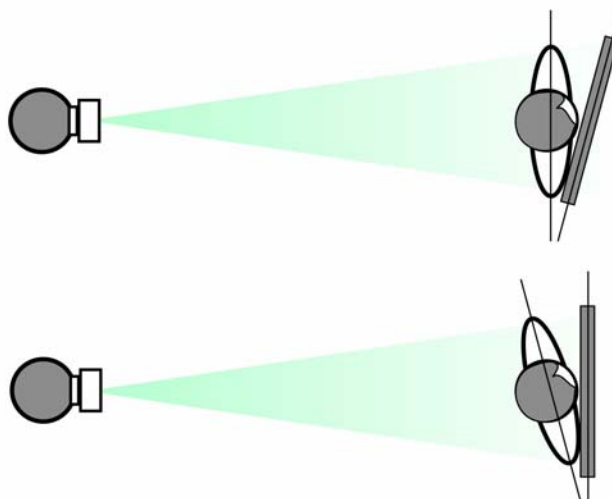


Figure 3.13 Illustration of 2 examples of poor alignment

We can assess the alignment of these 3 elements from the imaging of sterno-clavicular joints on the chest radiograph. With regard to the distance **Figure 3.14** shows a good example and **Figure 3.15** shows “Poor” imaging of the sterno-clavicular joints on the chest radiograph. The difference of the distances ‘a’ and ‘b’ in **Figure 3.15** must not be more than 5mm.

To avoid overlapping of the clavicles on the apices of the lungs, the shoulders of the patient must be pressed well toward the X-ray film cassette, as with the positioning of the scapula.

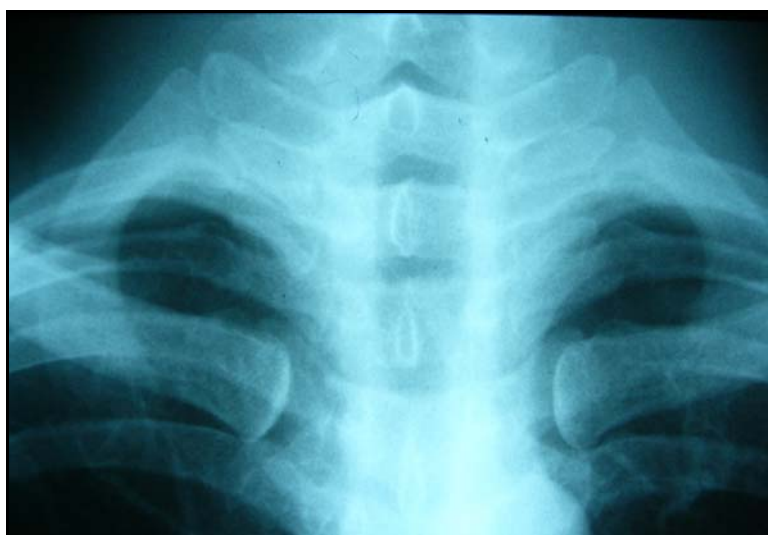

Figure 3.14 Good positioning of clavicles

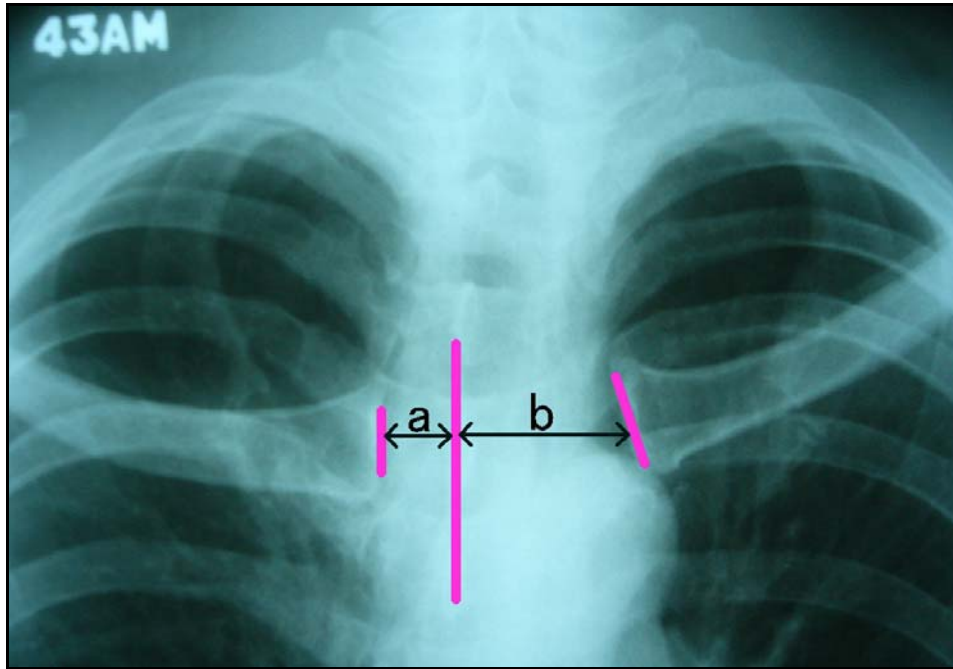


Figure 3.15 Bad positioning of clavicles

Your findings:

The sterno-clavicular joints are visualized at an unequal in distance.

Suggested actions for improvement:

- Ask radiographers about patient positioning
- Ask radiographers about the location of the cassette
- Ask radiographers about the direction of the X-ray beam
- Suggest that the radiographers press the shoulders of the patient further forward

iv. Position of clavicles

- If you observe that the clavicles are visualized apart from the 4th rib bones on X-ray film, you should tick YES for “Position of clavicles”.

The clavicles of the patient must be placed at any part of 4th posterior rib bone on the X-ray film. To avoid overlapping of the clavicles on the apices of the lungs, the shoulders of the patient must be pressed well toward the X-ray film cassette, as with the positioning of the scapula.

Figure 3.16 shows an ideal positioning of clavicles and *Figure 3.17* shows an unacceptable example of positioning of clavicles on the X-ray film.

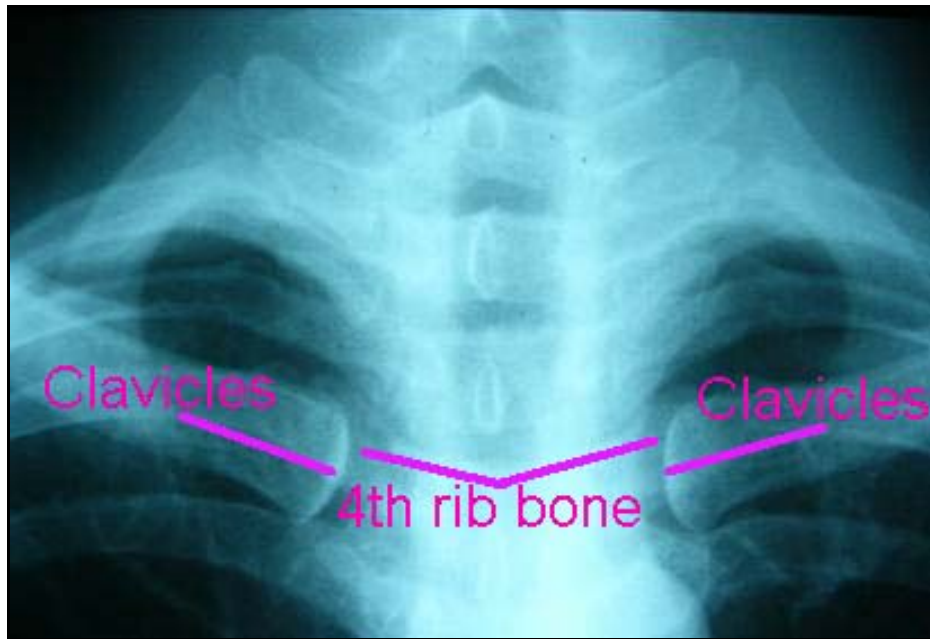


Figure 3.16 Ideal positioning of clavicles

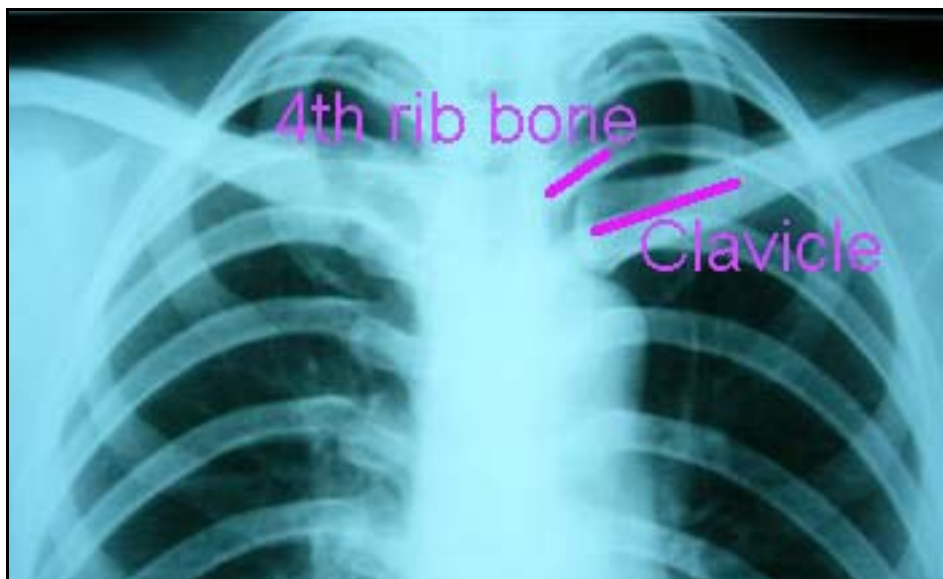

Figure 3.17 Improper positioning of clavicles

Your findings:

The clavicles are visualized apart from 4th rib bones

Suggested actions for improvement:

Please ask radiographers about

- the patient positioning
- the center beam of the X-ray beam

v. Position of scapulas

- If you observe that the right or left scapula, or both are visualized more than 1 cm in the lung fields, you should tick YES for “Position of scapulas”.

The shoulders of the patient should be pressed well forward to the X-ray film cassette to avoid overlapping the imaging of scapulas in the lung fields. **Figure 3.18** shows the examples of excellent and unacceptable positioning of scapulas on the chest radiograph. In the unacceptable imaging, scapula are overlapped in the lung field. With regard to the patients who are not easily able to move their shoulders, just press their shoulders toward the X-ray film cassette within their range of movement.

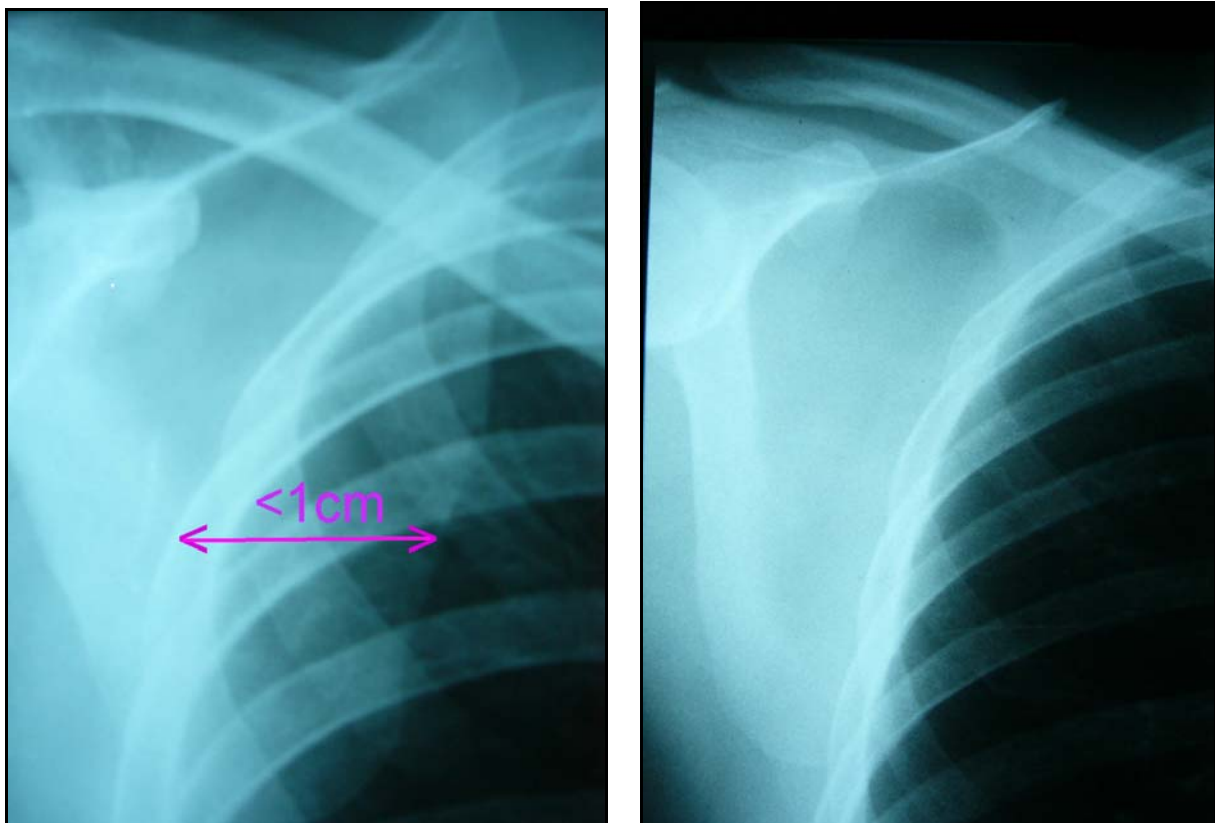


Figure 3.18 Bad positioning (left) and good positioning (right) of scapula

Your finding:

The right or left scapula, or both are visualized in the lung fields

Suggested actions for improvement:

- Ask radiographers about patient positioning
- Suggest that the radiographers press the shoulders further forward

vi. Asymmetric density of lungs

- If you observe that the density of right and left lungs is not symmetric (except in the case where this caused by physical deformity of the patient), you should tick YES for “Asymmetric density of lungs”.

Both the right and left lungs must be imaged with symmetric density on the X-ray film. **Figure 3.19** shows an illustration of an example of unacceptable asymmetric lung field density. By technically improper usage of the grid and arrangement of the X-ray tube, this asymmetric density of lungs will appear. **Figure 3.20** shows an illustration of wrong arrangement of X-ray grid causing asymmetric density imaging of lung fields.

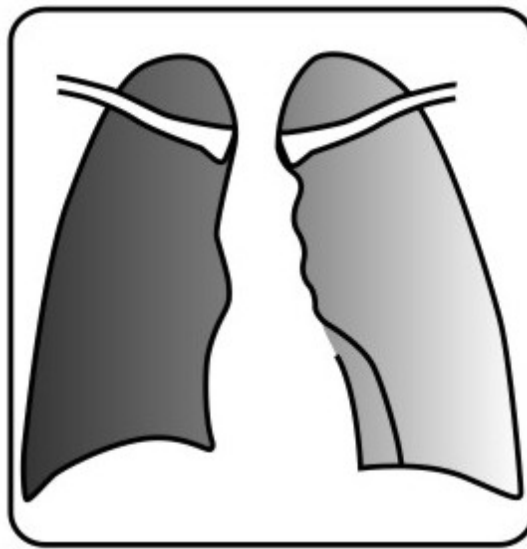


Figure 3.19 Asymmetric density of lungs




Figure 3.20 Cause of asymmetric density imaging of lung fields

Figure 3.21 shows a sample X-ray film which lacks smoothness of lead strip lines caused by improper alignment of the X-ray and grid. Wrong alignment of X-ray beam and grid causes asymmetric density imaging of lung fields.

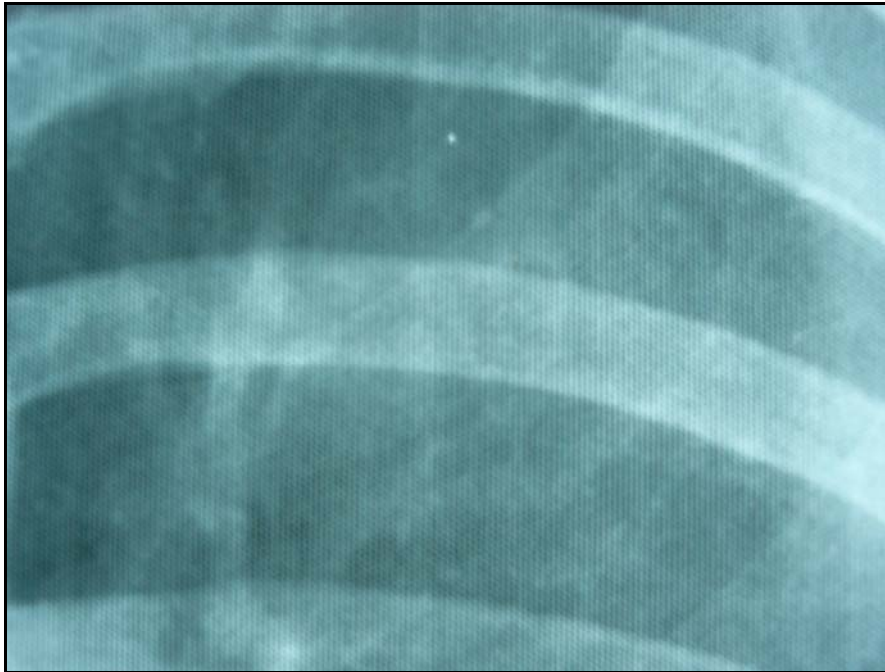


Figure 3.21 Lack of smoothness with lead strip lines due to improper alignment of grid

Your finding:

The density of right and left lungs is not symmetric

Suggested actions for improvement:

Please ask radiographers about

- the way they use the grid
- the X-ray tube arrangement

vii. Foreign substances

- If you observe that foreign substance(s) are visualized in the lung fields, you should tick YES for “Foreign substances”.

Careless preparation may visualize unnecessary substances on the X-ray film. **Figure 3.22** and **3.23** show some examples of unacceptable imaging of foreign substances on the chest radiographs caused by carelessness of radiographers.

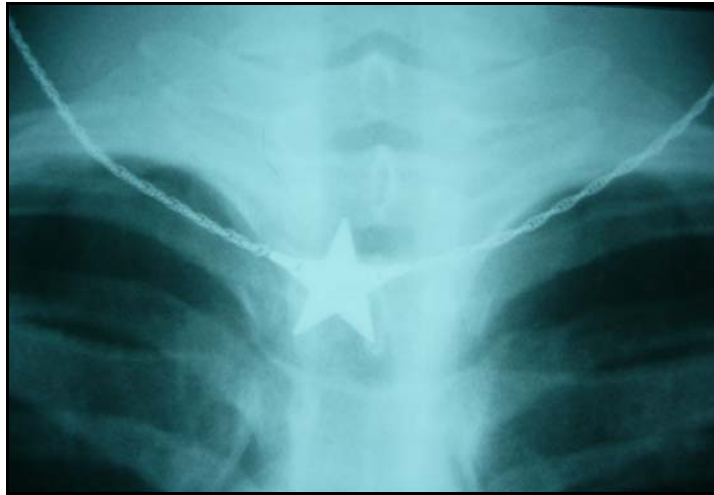

Figure 3.22 A necklace placed in the lung field

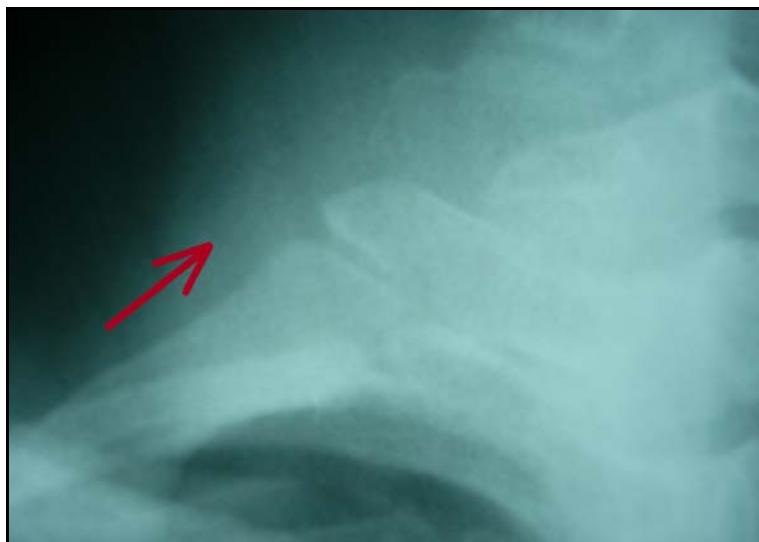

Figure 3.23 Long hair placed in the lung field

Your finding:

Foreign substances are visualized

Suggested action for improvement:

- Ask radiographers about the preparation of patients

3) Density

- First, you should score the density at each of four important areas: 1) lung field, 2) lung periphery, 3) mediastinum, and 4) cardiac shadow. And then, you should sum up the four scores and grade it as “Good” with 4-5, “Fair” with 6-9, and “Poor” with 10-12, for overall assessment on Density of the chest radiograph according to the sub-total score.
- Each of the four densities is categorized; “Good”, “Fair”, or “Poor”. When the density is almost the same as that at the corresponding area of the model film which has been chosen by the authorities, you should score it as “Good”. Or when it is far from that, too dark or too light, you should score it as “Poor”. “Fair” is a category between “Good” and “Poor”.
- The good quality of density in the mediastinum part can be assessed by the barely visible contour of the 10th thoracic vertebra. With regard to the area of cardiac shadow, good quality density can be assessed by the visible left lateral line of the descending aorta.
- When you can use a densitometer, you should score the density of each of the four parts based on the results you measured.

The relative darkness in a particular area of X-ray film is called density. The quantitative density of X-ray film can be measured by a regular type of densitometer, and the value of the density ranges from 0.0 to 4.0. The densitometer is the device that provides the numeric value of the density of X-ray film that humans can not determine. *Figure 3.24* shows a view for measuring the density of chest radiographs by X-Rite 301.

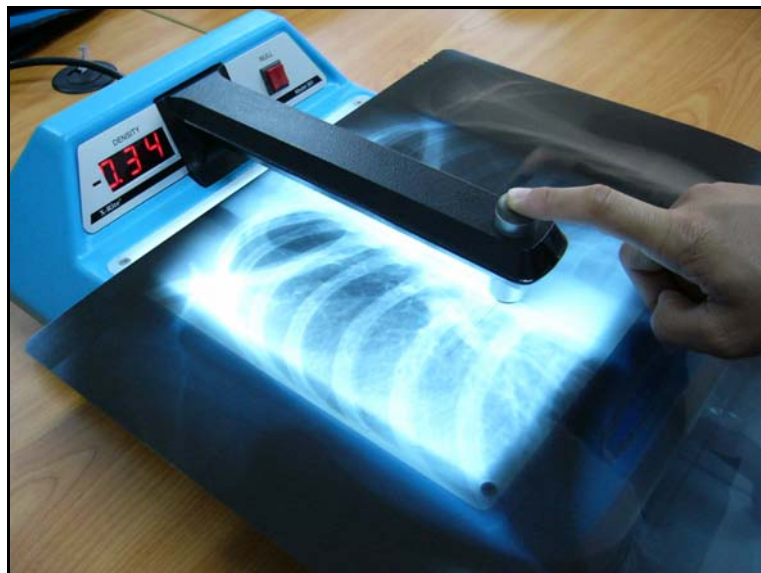

Figure 3.24 Density measuring device

- X-Rite 301 costs USD 1,575
- The portable type of densitometer, X-Rite 331, costs USD 1,000

With regard to the assessment of quality of chest X-ray, there are 4 specific areas that have to be more carefully diagnosed. **Figure 3.25** shows an illustration of the 4 most important areas in the lung fields:

- 1) lung field 2) lung periphery
- 3) mediastinum 4) cardiac shadow

Both Density and Contrast are measured at these 4 areas on the chest radiograph.

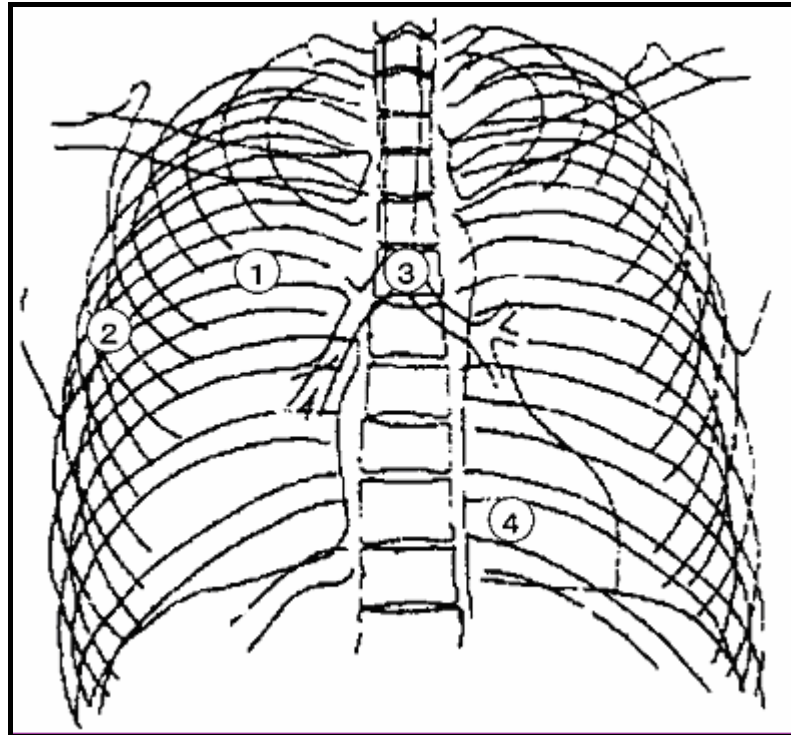


Figure 3.25 Four most important areas in the lung fields

The Research Institute of Tuberculosis, Japan Anti-Tuberculosis Association, empirically places the following levels of density at the four areas as one of the radiographs with the highest quality (**Figure 3.26**);

- 1) Lung field: 1.86 2) Lung periphery: 0.68
- 3) Mediastinum structure: 0.51 4) Cardiac shadow: 0.53




Figure 3.26 Arrows show the density levels in the 4 most important areas

Figure 3.27 shows an excellent sample of density for a chest radiograph and we can visually clarify the differences without a densitometer.

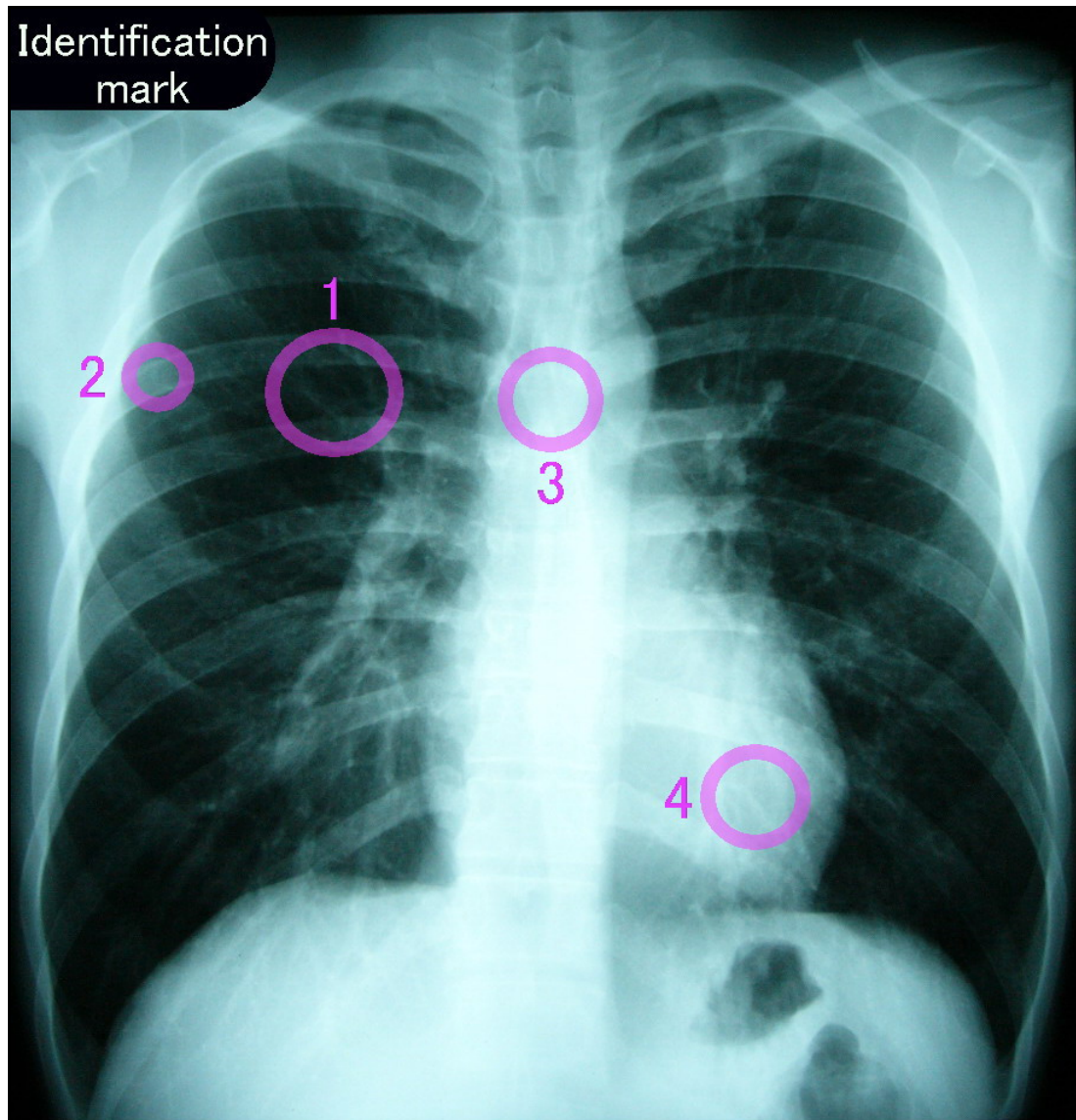


Figure 3.27 Excellent quality of chest radiograph sample

<u>1) Lung field:</u>	<u>1.86</u> (2.00: The density of sample X-ray)
<u>2) Lung periphery:</u>	<u>0.68</u> (0.82: The density of sample X-ray)
<u>3) Mediastinum structure:</u>	<u>0.51</u> (0.60: The density of sample X-ray)
<u>4) Cardiac shadow:</u>	<u>0.53</u> (0.53: The density of sample X-ray)

Your findings:

High density

Suggested action for improvement:

Please ask radiographers about

- the X-ray factors (excessive kV and /or mAs?)
- the temperature of the developer (too high?)
- the developing time (too long?)

Your findings:

Low density

Suggested action for improvement:

Please ask radiographers about

- the X-ray factors (low kV and/or mAs?)
- the expiration date of X-ray film (already expired?)
- the combination of screen and film (mismatching?)
- the quality of developing solution (too old?)
- the temperature of developer (too cold?)
- the developing time (too short?)

If:

- If something is wrong with the X-ray equipment, contact the X-ray engineers of manufacturers and/or local agent and check the function of X-ray exposure factors such as kV, mA and exposure time.

4) Contrast

- First, the same as Density, you should score the contrast at each of four important areas: 1) lung field, 2) lung periphery, 3) mediastinum, and 4) cardiac shadow. And then, you should sum up the four scores and grade it as “Good” with 4-5, “Fair” with 6-9, and “Poor” with 10-12, for overall assessment on Contrast of the chest radiograph according to the sub-total score.
- Each contrast at the four areas is categorized as “Good”, “Fair”, or “Poor” as follows;

1) Lung field

“Good”: the pulmonary vessels can be easily traced at the lung fields.

“Fair” : not Good but not Poor.

“Poor” : it is impossible to trace the pulmonary vessels in the lung fields.

2) Lung periphery

“Good”: the pulmonary vessels can be easily traced to the lung periphery, and also the border line between the chest wall and the lung field is clearly visible.

“Fair” : not “Good” but not “Poor”.

“Poor” : it is impossible to trace the pulmonary vessels in the peripheral part of the lung, or the border line between the chest wall and the lung field is obscure.

3) Mediastinum

“Good”: the trachea and both main tracheal branches are clearly visible.

“Fair” : not “Good” but not “Poor”.

“Poor” : it is impossible to identify the trachea or main tracheal branches.

4) Cardiac shadow

“Good”: the pulmonary vessels can be easily traced behind the cardiac shadow.

“Fair” : not “Good” but not “Poor”.

“Poor” : it is impossible to trace the pulmonary vessels behind the cardiac shadow.

Contrast is the subtraction of density between different areas in the imaging subject. When viewing radiographs with inadequately low contrast, it is difficult to differentiate density areas in the subject. On the other hand excessively high contrast radiographs may not allow us to visualize important subtle differences in density between different areas. *Figure 3.28* shows the samples of inadequately low contrast and higher contrast imaging of X-ray films.

Higher contrast imaging →

Lower contrast imaging →




Figure 3.28 High (above) and low (below) contrast imaging

Proper contrast imaging of chest radiograph can visualize the structure of pulmonary vessels behind the bones unlike excessively high contrast imaging in which we cannot trace the structures. Schematic illustration and figures (*Figure 3.29 – Figure 3.31*) show the differences in bone and lung fields between excessively high and proper contrast imaging.

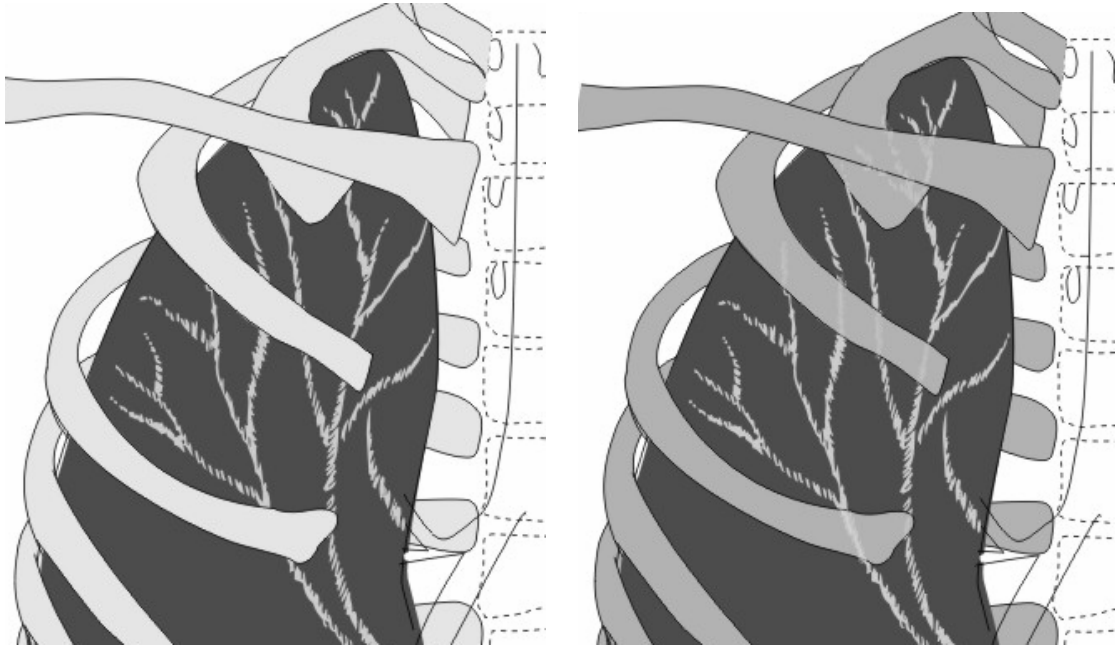


Figure 3.29 Excessively high contrast (left) and proper contrast (right) imaging

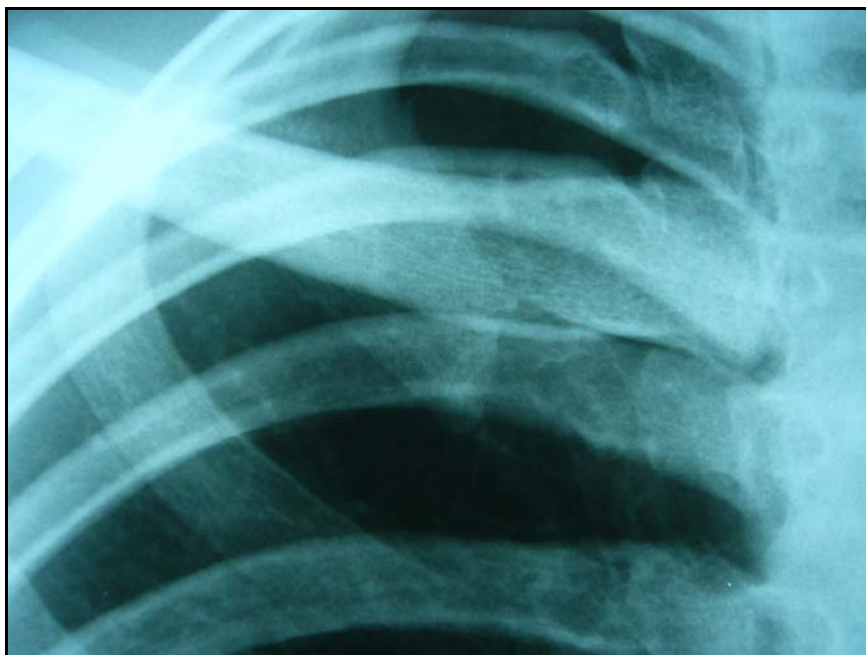


Figure 3.30 Improper contrast: Excessively high contrast between rib bones and lung field

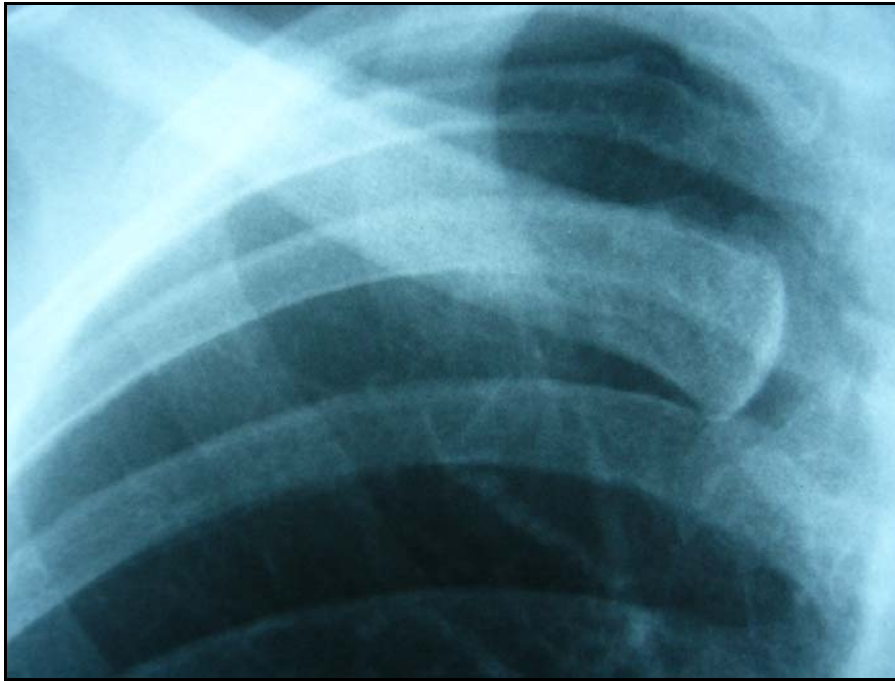


Figure 3.31 Good contrast imaging: Pulmonary vessels are barely visible behind the bones

Proper contrast imaging of chest radiograph must visualize all the clinically important structures present in lung fields at appropriate density for the interpretation done by chest physicians. **Figure 3.32 - Figure 3.35** show samples of excellent contrast at the 4 important areas of the chest radiograph. The red lines point out what you should pay special attention to on the film.

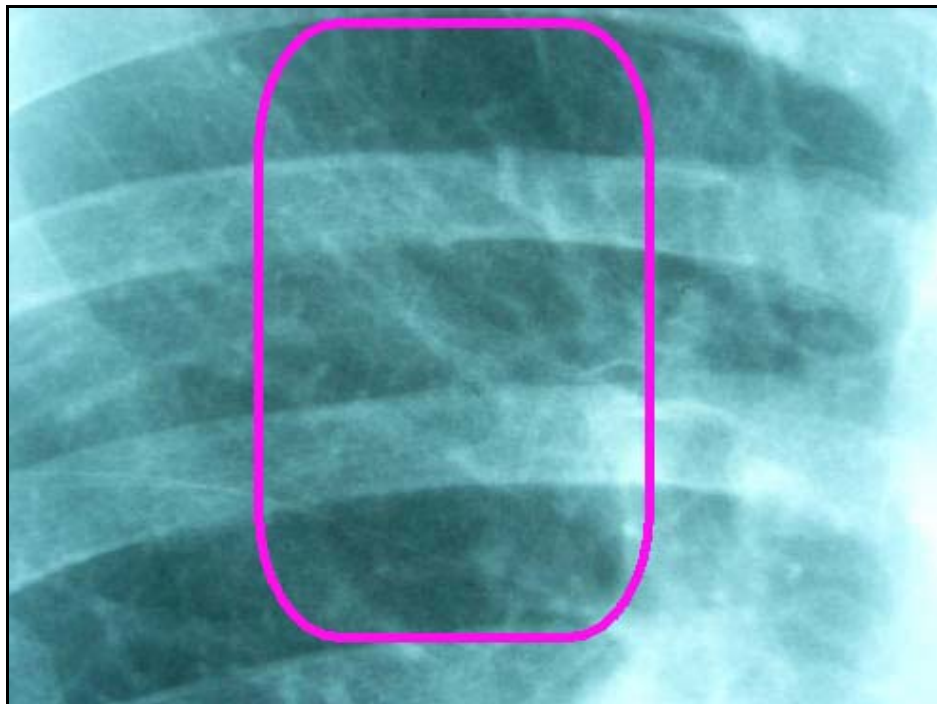


Figure 3.32 Sample of ideal contrast of the lung field

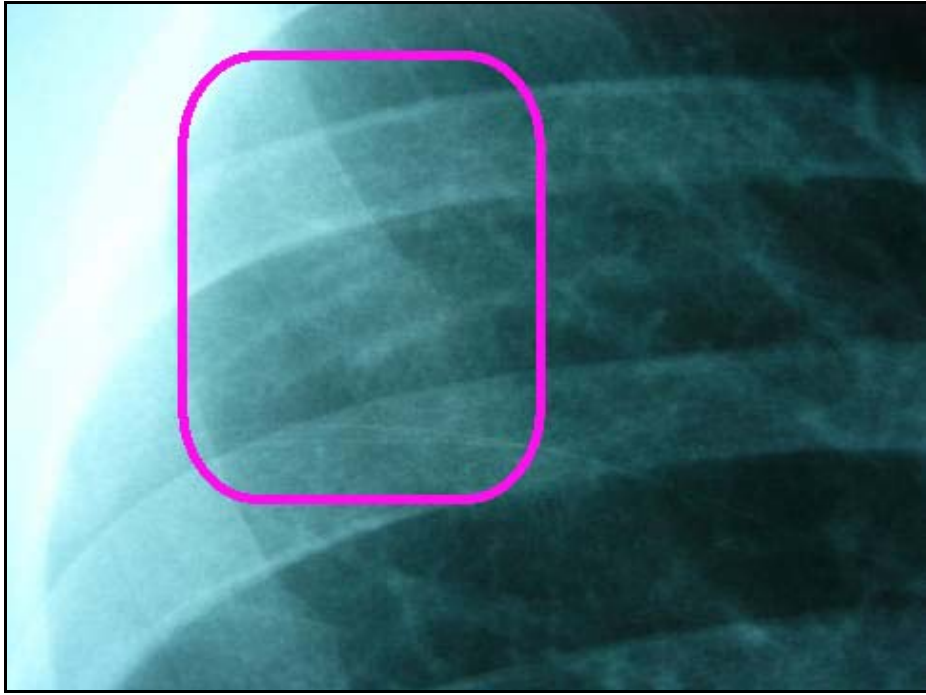


Figure 3.33 Sample of ideal contrast of the lung periphery

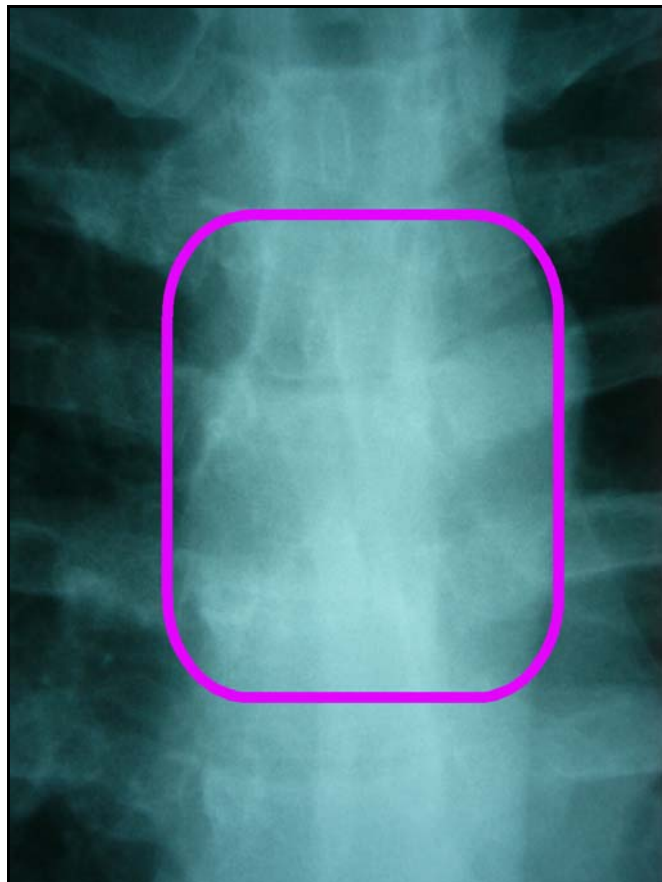


Figure 3.34 Sample of ideal contrast of the mediastinum structure

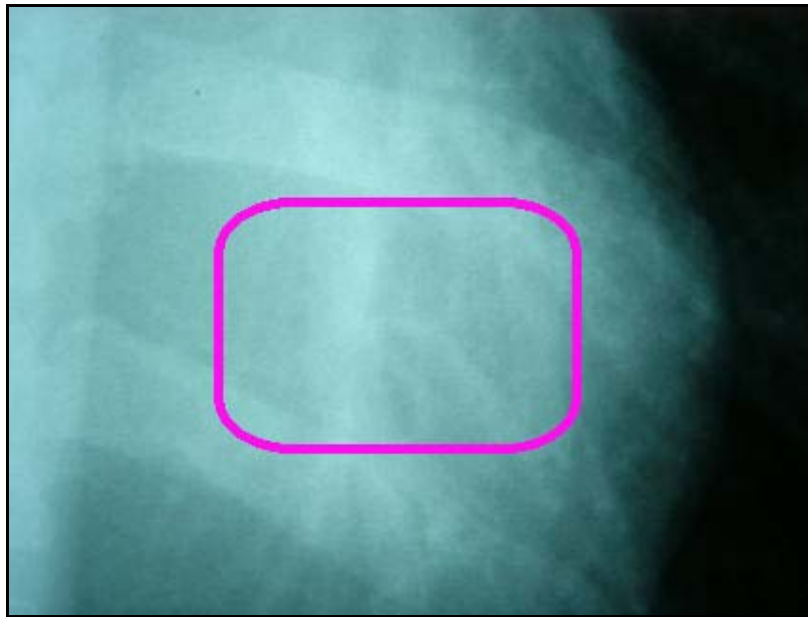


Figure 3.35 Sample of ideal contrast of the cardiac shadow

Your finding:

High contrast

Suggested actions for improvement:

Please ask radiographers about

- the X-ray tube voltage, kV (too low in kV?)
- the temperature of developer (too warm?)

Your finding:

Low contrast

Suggested actions for improvement:

Please ask radiographers about

- the temperature of developer (too cold?)
- the expiration date of X-ray film (already expired?)
- the quality of developing solution (too old?)
- the developing time (too long?)
- scattered radiation (no grid used?)
- light leakage in the darkroom

If:

- If there is something wrong with the X-ray equipment, contact the X-ray engineer and check the function of X-ray exposure factors such as kV, mA and exposure time.

5) Sharpness

- “Good”: the pulmonary vessels are clearly visible in the entire left lung fields, especially around the left part of the cardiac shadow.
- “Fair” : the pulmonary vessels are clearly visible in the upper left lung fields, but obscure around the left part of the cardiac shadow.
- “Poor” : the pulmonary vessels are obscure in the entire left lung fields (*Figure 3.38*).

Sharpness is the appearance of the edge between 2 density areas in the imaging subject. The inadequate blurring of edges in the imaging subject on the X-ray film makes it difficult to differentiate the structure of the subject. *Figure 3.36* and *Figure 3.37* show the samples visualizing the structure of inadequate and adequate sharpness.




Figure 3.36 Poor sharpness (left) and excellent sharpness (right)

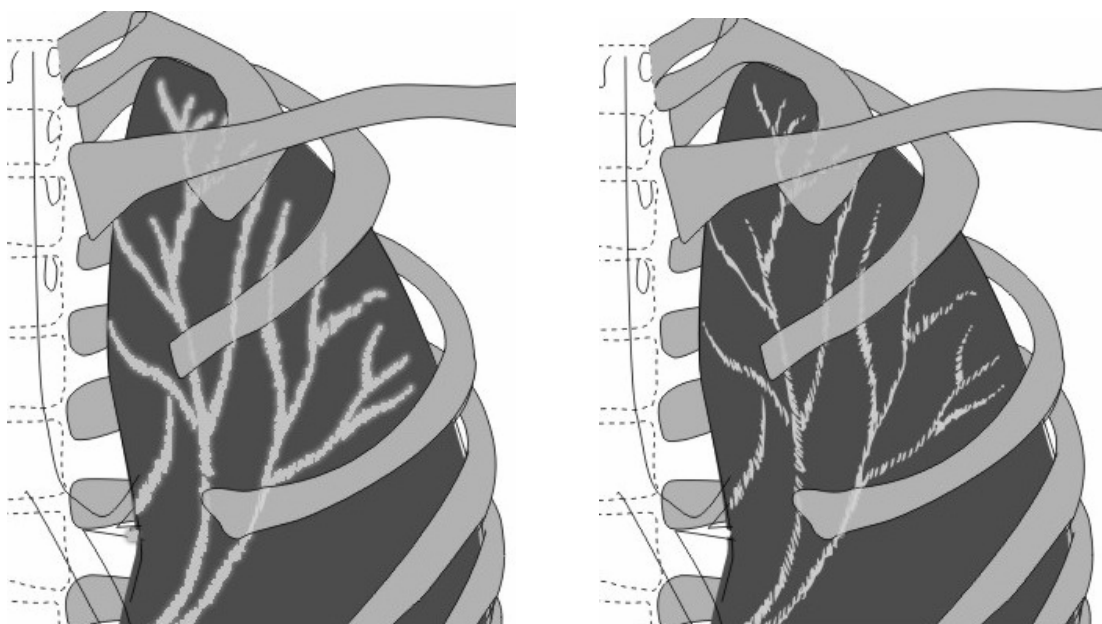


Figure 3.37 “Poor” sharpness (left) and “Good” sharpness of pulmonary vessel (right)

The quality of sharpness around the left lower part of the cardiac shadow should be carefully assessed because the lung surrounding the heart area moves by heart stroke motion (*Figure 3.38*). Shorter exposure time (less than 0.05 seconds) is recommended to produce better sharpness of the chest radiograph.

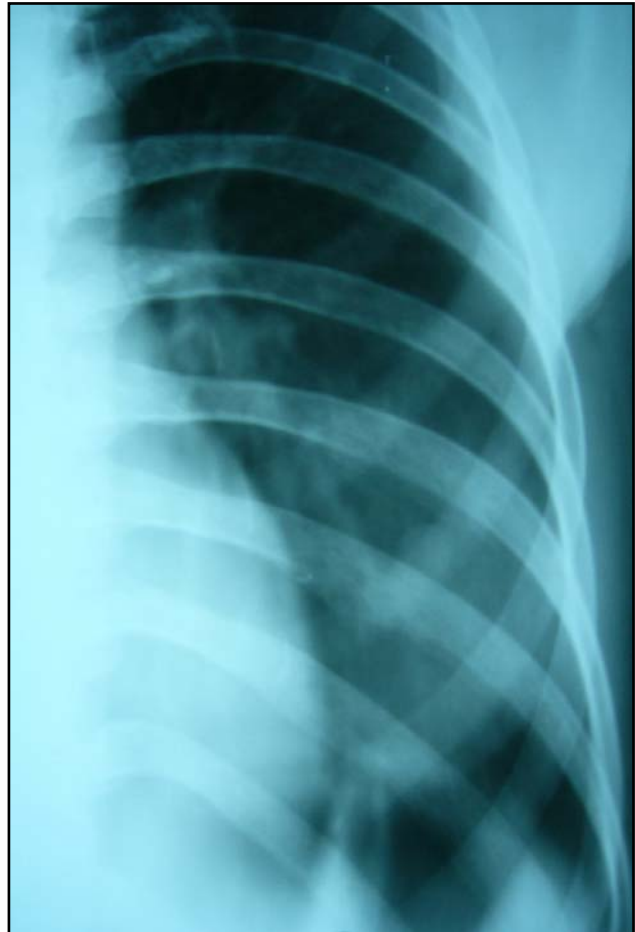


Figure 3.38 “Poor” sharpness in the imaging of pulmonary vessels

Your finding:

Lack of sharpness

Suggested actions for improvement:

Please ask radiographers about

- the exposure time (too long?)
- the combination of screen and film (not matching?)
- the rejection technology for scattered radiation (no grid used?)
- the distance between focus and film (too short?)
- the collimation of X-ray exposure (too big?)

6) Artifacts

- “None” : no artifacts in the lung fields.
- “Slight” : small and slight artifact(s) in the lung fields, to some degree, but in which your diagnosis is not disturbed.
- “Present”: clear and wide artifact(s) in the lung fields to the degree to which your diagnosis is disturbed.

Artifacts are unwanted imaging mainly caused by mishandling of X-ray film, dirty stains on the intensifying screen, improper processing of X-ray film, etc. **Figure 3.39 - Figure 3.48** show some examples of poor imaging quality by unacceptable artifacts on the chest radiograph.

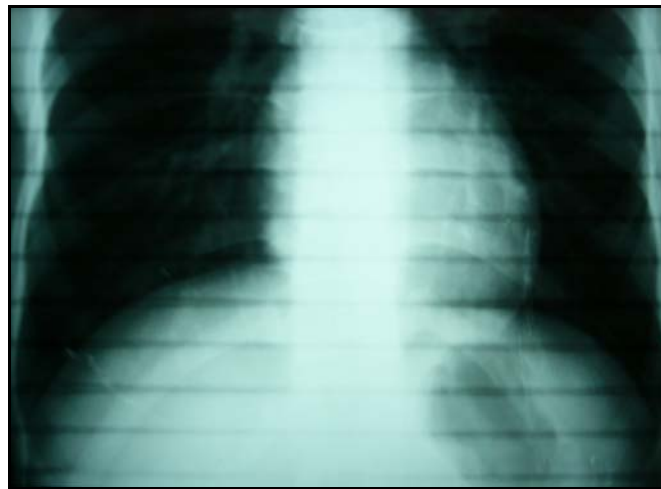


Figure 3.39 Improper processing of X-ray film by automatic processor

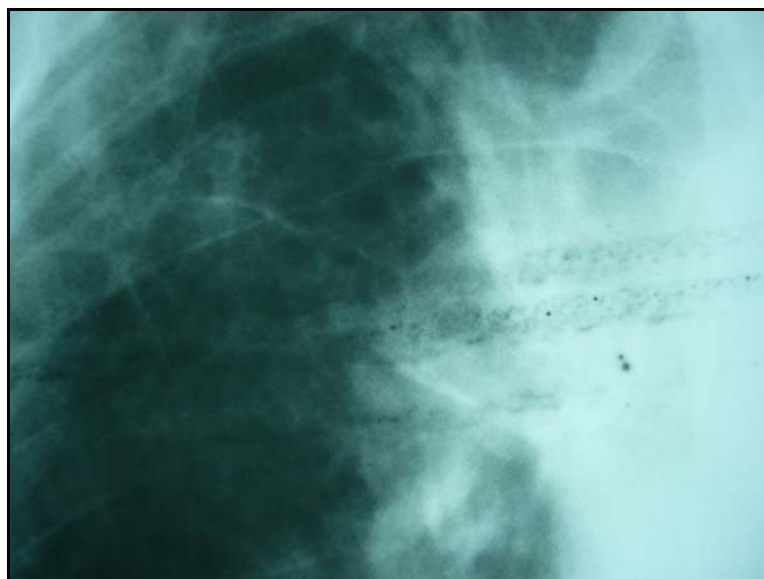


Figure 3.40 Dirty stains on intensifying screen

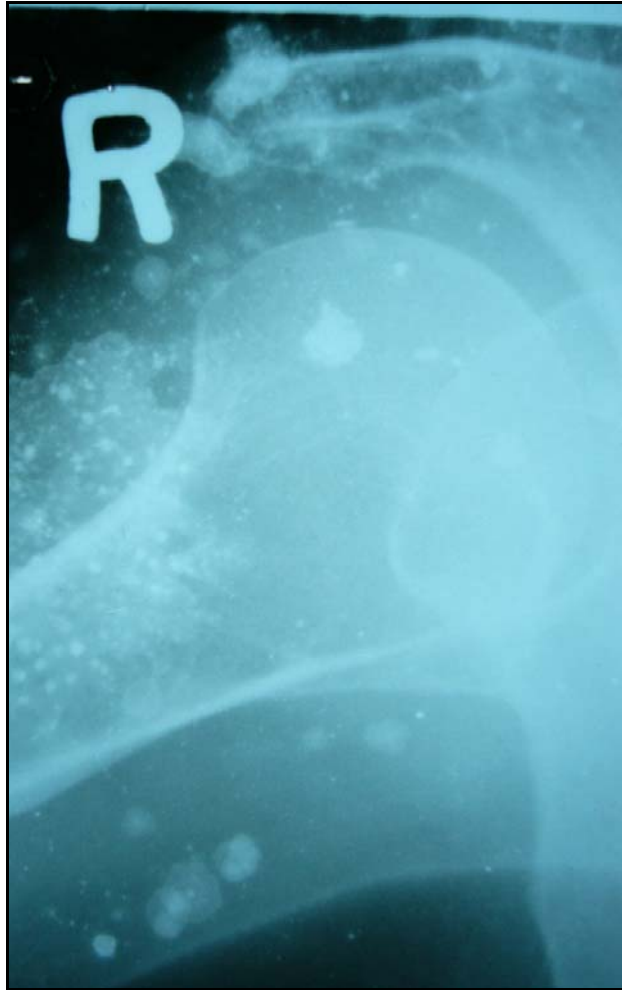


Figure 3.41 Dirty stains on intensifying screen

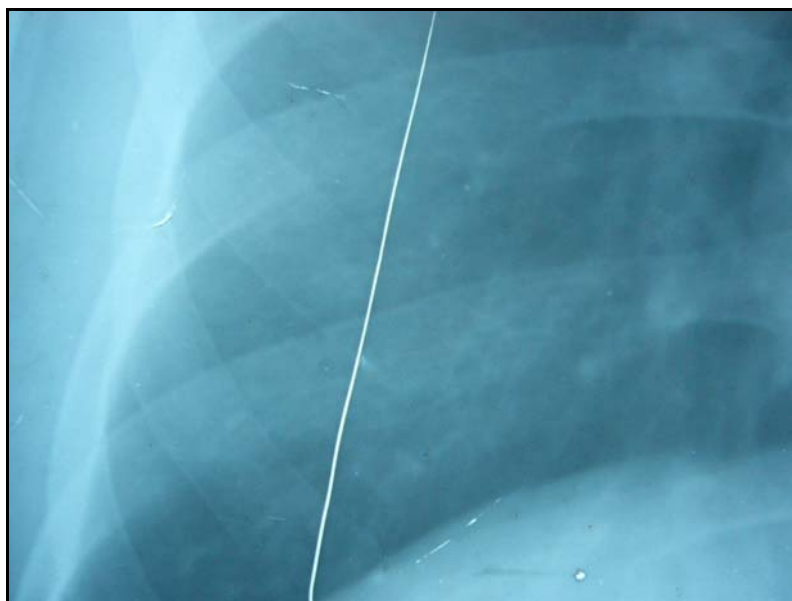


Figure 3.42 Scratch marks

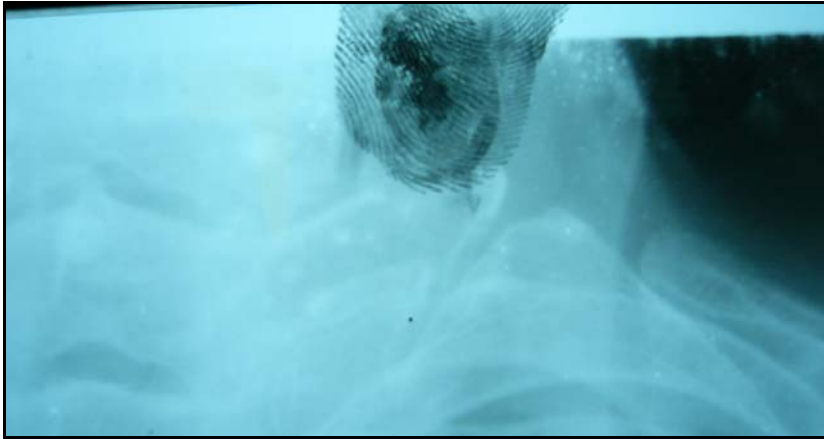


Figure 3.43 Handling by dirty fingers

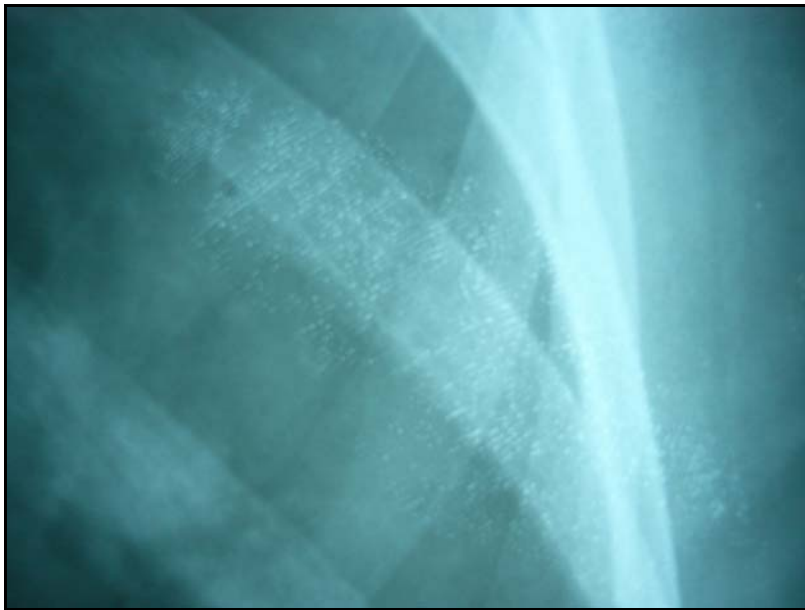


Figure 3.44 Handling with dirty fingers

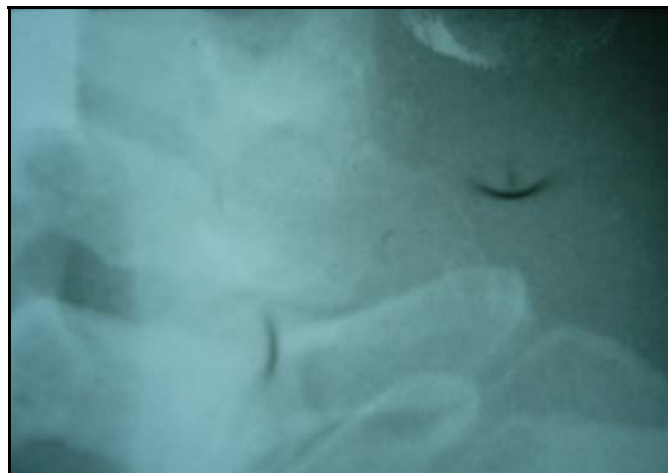

Figure 3.45 Mishandling of X-ray film

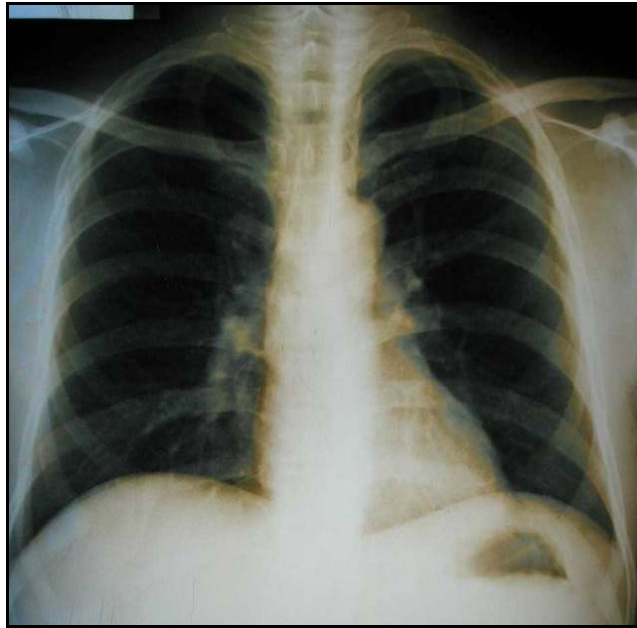


Figure 3.46 Improper processing of X-ray film

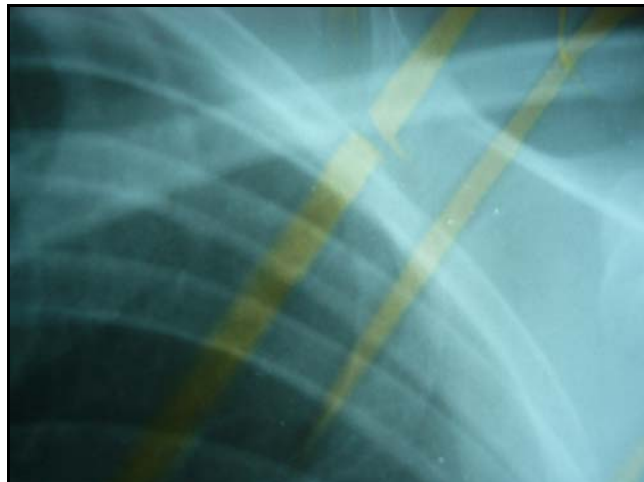

Figure 3.47 Improper processing of X-ray film

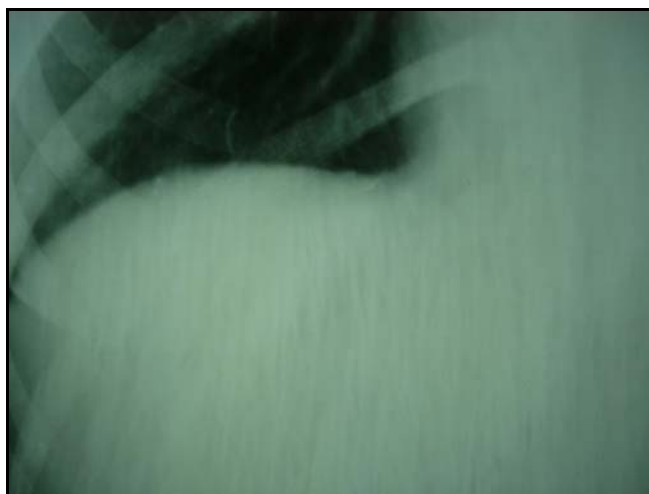


Figure 3.48 Use of expired processing solutions

Your finding:

Various artifacts(s) are found in the lung fields

Suggested actions for improvement:

Please ask radiographers about

- light leakage in the darkroom
- the manner of handling the X-ray film
- the condition of the screen (too dirty?)
- the condition of their hands (too dirty?)
- the condition of the developing solution (too dirty?)
- the condition of the fixing solution (too dirty?)
- the condition of the water (too dirty?)
- the condition of the drying process (too dusty?)
- the condition of the automatic processor (no regular maintenance?)

If:

- If an automatic processor is not working properly, contact the X-ray engineer in the local agent for calibration and repair work.

7) Overall assessment result and actions to be taken

Each factor is to be scored using the following scoring system:

1="Good/None", 2="Fair/Slight", and 3="Poor/Present".

The overall assessment of chest radiograph can be decided by the total score for the six factors, which ranges from 6 to 18 points.

- If the total score is 6 or 7, you should grade it as "Excellent".
- If the total score is 8-11 without any "Poor/Present", you should grade it as "Good".
- If the total score is 8-13 with 2 "Poor/Present"s or less, you should grade it as "Fair".
- And if the total score is 14 or more, or 3 "Poor/Present"s or more, you should grade it as "Poor".

If the overall assessment is "Fair" or "Poor", the TB supervisor should discuss the assessment results with the physicians and radiographers, and try to seek some possible solutions to improve the quality of the chest radiograph. When you can not find the causes and the definite solutions to solve the problems, you should ask a specialist for further support.

❖ Radiation protection

Radiation protection for the gonads is not directly related to the quality of chest radiography but it is important to avoid exposing the patients to unnecessary radiation exposure. In cases where no protection material is available, appropriate collimation can improve the sharpness by reducing the scattered radiation thereby avoiding unnecessary radiation to the gonads. *Figure 3.49* is a good sample of a chest radiograph that shows appropriate protection for gonads. *Figure 3.50* shows 2 examples of improper collimation of chest radiograph.

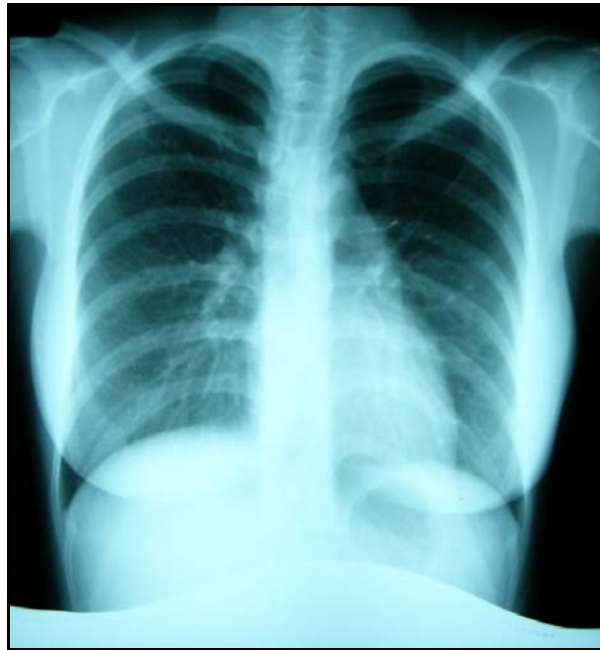

Figure 3.49 Gonads of young female are properly protected

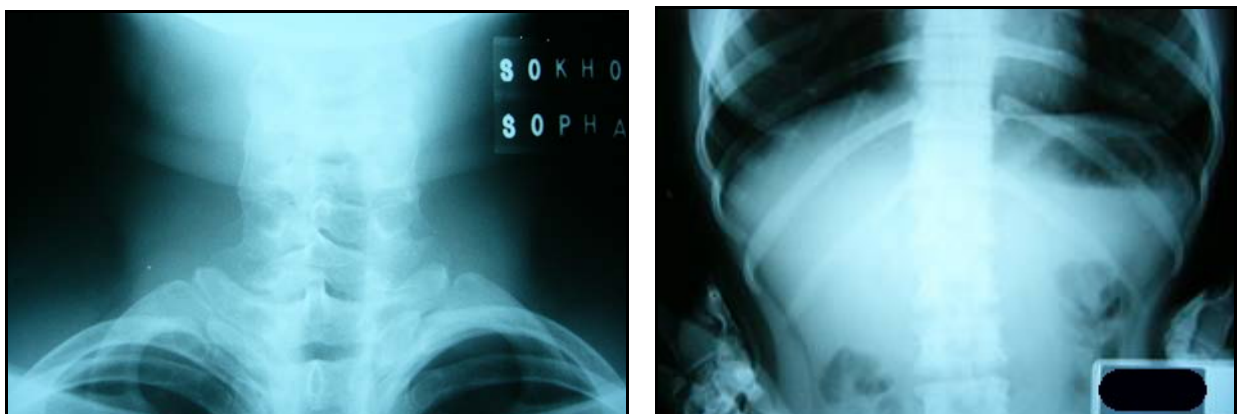


Figure 3.50

Two samples of inappropriate collimation of X-ray beam for the chest radiograph

IV. How to improve the quality of chest radiography for TB control

The assessment method presented in this Handbook can be applied to various settings in order to improve the quality of chest radiographs. Let us introduce three major ways to utilize it as a tool: Routine Internal Quality Control, External Quality Assessment at a district hospital, and External Quality Assessment by systematic review.

Each of these three activities has to be carried out with support from the corresponding level as outlined: Routine Internal Quality Control should be supported by the administrative department of the district hospital, External Quality Assessment at a district hospital should be supported and coordinated with the intermediate level, and External Quality Assessment by systematic review should be supported and coordinated with the National TB Program.

Routine Internal Quality Control

Medical staff at a district hospital should be engaged in routine internal quality control within the hospital by themselves. This, for example, includes the following activities.

- 1) Regular maintenance or checking of X-ray equipment, accessory devices, and chemicals and consumables.
- 2) Self check of chest radiographs routinely taken, with reference to the Handbook, the assessment sheet or other educational materials.
- 3) Feedback of low quality chest radiographs to the radiographer by the physician.

External Quality Assessment by TB supervisor at a district hospital on the spot

The TB supervisor in collaboration with physician(s) and radiographer(s) should be engaged in external quality control at a district hospital, using the assessment sheet on the spot.

1. Preparation

- 1) Three sorts of technical staff: The TB supervisor, physician(s) who usually interpret chest radiographs, radiographer(s) who are actually engaged in exposure and film development, and others.
 - 2) A model chest radiograph which has been chosen by authorities and a film viewer.
 - 3) Some copies of the assessment sheet and pens or pencils.
 - 4) Three to five representative chest radiographs to be assessed, which have been taken preferably on different weeks or months at the medical facility.
2. Assess the films by the participants according to the handbook one by one.
 3. If any films are graded as “Fair” or “Poor” in the overall assessment result, discuss some possible causes and actions to be taken to improve the quality at the facility.
 4. Record the overall assessment results on the form (see Annex 3).
 5. Repeat this Quality Assurance cycle and compare a series of overall assessment results at

the facility.

6. Ask a specialist for further support if you can not attain “Excellent” or “Good” in the overall assessment results.

External Quality Assessment by systematic review

The purpose of this activity is to improve the quality of chest radiography through not only personal effort but organized efforts in a larger area served by several hospitals or more.

1. Preparation
 - 1) Set up a panel team consisting of some persons experienced in the assessment techniques.
 - 2) A model chest radiograph which has been chosen by authorities
 - 3) Film viewer(s), some copies of the assessment sheet, and pens or pencils
 - 4) A film densitometer if possible
 - 5) Three representative films that have been assessed at each medical facility by the participants
2. Assess the films by the panel team according to the handbook one by one, being open to all the participants.
3. Compare the overall assessment results by the panel team with those on the spot and discuss the differences if any.
4. If any films are graded as “Fair” or “Poor” in the overall assessment result, discuss some possible causes and actions to be taken to improve the quality at the facility.
5. Repeat this Quality Assurance cycle and ensure that the proportion of “Excellent” and “Good” increases as a whole. (see Annex 4)

Annex 1: References for further reading

This is a list of references for further reading in order to improve your understanding of the details in respect to the fields of clinical, technical and quality assessment of chest radiography.

These two references describe the basic principles of chest radiography for TB care. There are 17 standards included, among which standards numbers 4, 5 and 6 are related to the basic principles of chest radiography for TB care.

1. Tuberculosis Coalition for Technical Assistance (TBCTA), *International Standards for Tuberculosis Care*, The Hague, TBCTA, 2006.
2. TBCTA, *Handbook for Using the International Standards for Tuberculosis Care*, The Hague, TBCTA, 2007.

This reference mentions the role of chest radiography by use of the algorithm for the diagnosis of TB in HIV-prevalent settings.

3. Stop TB Dept., WHO, *Improving the diagnosis and treatment of smear-negative pulmonary and extrapulmonary TB among adults and adolescents; Recommendations for HIV-prevalent and resource-constrained settings*, WHO, 2007.

These two references are recommended to improve your clinical capability for interpretation of chest X-ray.

4. Ellis, Stephen M, *The WHO manual of diagnostic imaging: Radiographic Anatomy and Interpretation of the Chest and the Pulmonary System*, WHO, 2006.
5. Daley, Charles L., Michael B. Gotway, Robert M. Jasmer, *Radiographic Manifestations of Tuberculosis*, Francis J. Curry National Tuberculosis Center, 2006.

These two references are recommended to improve your radiographic technique.

6. Corr, Peter, *Pattern recognition in diagnostic imaging*, WHO, 2001.
7. Sandström, Staffan, *The WHO manual of diagnostic imaging: Radiographic Technique and Projections*, WHO, 2003.

These two references are recommended to improve your understanding of regular maintenance technique for X-ray equipment and other accessory equipment.

8. Loyd, Peter J., *Quality assurance workbook: for radiographers & radiological technologists*, WHO, 2001.
9. McClelland, Ian R., *X-ray equipment maintenance and repair workbook: for radiographers & radiological technologists*, WHO, 2004.

This is a comprehensive reference for layout of an X-ray department and guide for the purchasing process of X-ray equipment and other accessories.

10. Holm, Thure, *Consumer guide for the purchase of X-ray equipment*, WHO, 2000.

This is a comprehensive reference for understanding the quality assessment with quantitative and qualitative methods for chest radiographic imaging.

11. International Commission on Radiation Units and Measurement, *ICRU Report 70: Image Quality In Chest Radiography*, ICRU, 2003.

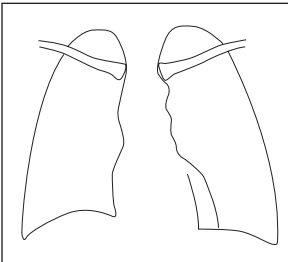
Annex 2: Assessment sheet & summary of the simple assessment procedures
Assessment Sheet for Imaging Quality of Chest Radiography

Date : / / 20

Name of Health Facility:

Date when film was taken / /

Patient Name or ID Number:

1) Identification marking of the patient		1. <i>Good</i>	2. <i>Fair</i>	3. <i>Poor</i>
2) Patient positioning “Good ” is the score of 0 or 1 excluding items i. or ii. “Fair” is neither “Good” nor “Poor”. “Poor” is a score of 5 or more, or any score with both i. and ii.		Please check the following 7 items: i. Defective lung fields <input type="checkbox"/> Yes or <input type="checkbox"/> No ii. Poor inspiration <input type="checkbox"/> Yes or <input type="checkbox"/> No iii. Oblique positioning <input type="checkbox"/> Yes or <input type="checkbox"/> No iv. Position of clavicles <input type="checkbox"/> Yes or <input type="checkbox"/> No v. Position of scapulas <input type="checkbox"/> Yes or <input type="checkbox"/> No vi. Asymmetric density of lungs <input type="checkbox"/> Yes or <input type="checkbox"/> No vii. Foreign substances <input type="checkbox"/> Yes or <input type="checkbox"/> No		
		1. <i>Good</i>	2. <i>Fair</i>	3. <i>Poor</i>
3) Density sub-total score 1. <i>Good (4-5)</i> 2. <i>Fair (6-9)</i> 3. <i>Poor (10-12)</i>	① Lung field	1. good	2. fair	3. poor
		If “2 or 3”, please specify your reason: i. Excessive, ii. Insufficient		
	② Lung periphery	1. good	2. fair	3. poor
		If “2 or 3”, please specify your reason: i. Excessive, ii. Insufficient		
	③ Mediastinum	1. good	2. fair	3. poor
	If “2 or 3”, please specify your reason: i. Excessive, ii. Insufficient			
	④ Cardiac shadow	1. good	2. fair	3. poor
	If “2 or 3”, please specify your reason: i. Excessive, ii. Insufficient			
4) Contrast sub-total score 1. <i>Good (4-5)</i> 2. <i>Fair (6-9)</i> 3. <i>Poor (10-12)</i>	① Lung field	1. good	2. fair	3. poor
	② Lung periphery	1. good	2. fair	3. poor
	③ Mediastinum	1. good	2. fair	3. poor
	④ Cardiac shadow	1. good	2. fair	3. poor
5) Sharpness		1. <i>Good</i>	2. <i>Fair</i>	3. <i>Poor</i>
6) Artifacts <div style="border: 1px solid black; padding: 5px; display: inline-block;"> 1. <i>None</i> 2. <i>Slight</i> 3. <i>Present</i> </div>	If “2 or 3 ”, please indicate the place of artifacts in this figure:			
<div style="border: 1px solid black; padding: 10px; text-align: center;"> Assessment Result: Total score for the 6 factors is _____ (6 – 18) </div>				
<u>Excellent:</u> 6 or 7 , <u>Fair:</u> 8-13 with 2 “Poor/Present”s or less		<u>Good:</u> 8-11 without any “Poor/Present” <u>Poor:</u> 14-18 or with 3 “Poor/Present”s or more		
Radiation protection for the gonads		Gonads are Protected Gonads are NOT protected		
Comments				Assessor

Summary of the simple assessment procedures

1) Identification marking of the patient

- “Good” example includes all the four identifications (name of patient, age, name of health facility, and date of examination) outside the lung fields.
- “Fair” example is missing 1 or 2 identifications of the four outside the lung fields.
- “Poor” example has no information and/or marking material placed in the lung fields.

2) Patient positioning

- i. Defective lung fields: If you observe that any defective part of the lung fields, even a small portion, exist in the X-ray film when you put the chest radiograph on a film viewer, you should tick YES for “Defective lung fields”.
- ii. Poor inspiration: If you find all of the lower line of the 10th rib (usually of the right lung) seen below the line of the right diaphragm, you should tick YES for “Poor inspiration”.
- iii. Oblique positioning: If you observe that the difference in the distances from the right or the left clavicles to the spinous process of thoracic vertebrae is more than 5mm, you should tick YES for “Oblique positioning”.
- iv. Position of clavicles: If you observe that the clavicles are visualized apart from the 4th rib bones on X-ray film, you should tick YES for “Position of clavicles”.
- v. Position of scapulas: If you observe that the right or left scapula, or both are visualized more than 1 cm in the lung fields, you should tick YES for “Position of scapulas”.
- iv. Asymmetric density of lungs: If you observe that the density of right and left lungs is not symmetric, you should tick YES for “Asymmetric density of lungs”.
- vii. Foreign substances: If you observe that foreign substance(s) are visualized in the lung fields, you should tick YES for “Foreign substances”.

3) Density

- First, you should score the density at each of four important areas: 1) lung field, 2) lung periphery, 3) mediastinum, and 4) cardiac shadow. And then, you should sum up the four scores and grade it as “Good” with 4-5, “Fair” with 6-9, and “Poor” with 10-12, for overall assessment on Density of the chest radiograph according to the sub-total score.
- Each of the four densities is categorized; “Good”, “Fair”, or “Poor”. When the density is almost the same as that at the corresponding area of the model film which has been chosen by the authorities, you should score it as “Good”. Or when it is far from that, too dark or too light, you should score it as “Poor”. “Fair” is a category between “Good” and “Poor”.
- The good quality of density in the mediastinum part can be assessed by the barely visible contour of the 10th thoracic vertebra. With regard to the area of cardiac shadow, good quality of density can be assessed by the visible left lateral line of the descending aorta.
- When you can use a densitometer, you should score the density of each of the four parts based on the results you measured.

4) Contrast

- First, the same as Density, you should score the contrast at each of four important areas: 1) lung field, 2) lung periphery, 3) mediastinum, and 4) cardiac shadow. And then, you should sum up the four scores and grade it as “Good” with 4-5, “Fair” with 6-9, and “Poor” with 10-12, for overall assessment on Contrast of the chest radiograph according to the sub-total score.
- Each contrast at the four areas is categorized as “Good”, “Fair”, or “Poor” as follows:
 - 1) Lung field: “Good”: the pulmonary vessels can be easily traced at the lung fields. “Fair”: not “Good” but not “Poor”. “Poor”: it is impossible to trace the pulmonary vessels in the lung fields.
 - 2) Lung periphery: “Good”: the pulmonary vessels can be easily traced to lung periphery, and also the border line between the chest wall and the lung field is clearly visible. “Fair”: not “Good” but not “Poor”. “Poor”: it is impossible to trace the pulmonary vessels in the peripheral part of the lung, or the border line between the chest wall and the lung field is obscure.
 - 3) Mediastinum: “Good”: the trachea and both main tracheal branches are clearly visible. “Fair”: not “Good” but not “Poor”. “Poor”: it is impossible to identify the trachea or main tracheal branches.
 - 4) Cardiac shadow: “Good”: the pulmonary vessels can be easily traced behind the cardiac shadow. “Fair”: not “Good” but not “Poor”. “Poor”: it is impossible to trace the pulmonary vessels behind the cardiac shadow.

5) Sharpness

- “Good”: the pulmonary vessels are clearly visible in the entire left lung fields, especially around the left part of the cardiac shadow.
- “Fair”: the pulmonary vessels are clearly visible in the upper left lung fields, but obscure around the left part of the cardiac shadow.
- “Poor”: the pulmonary vessels are obscure in the entire left lung fields (Figure 3.38).

6) Artifacts

- “None”: no artifacts in the lung fields.
- “Slight”: small and slight artifact(s) in the lung fields, to some degree, but in which your diagnosis is not disturbed.
- “Present”: clear and wide artifact(s) in the lung fields to the degree to which your diagnosis is disturbed.

7) Overall assessment result and actions to be taken

Each factor is to be scored using the following scoring system: 1=“Good/None”, 2=“Fair/Slight”, and 3=“Poor/Present”. The overall assessment of chest radiograph can be decided by the total score for the six factors, which ranges from 6 to 18 points. If the total score is 6 or 7, you should grade it as “Excellent”, if that is 8-11 without any “Poor/Present”, you should grade it as “Good”, if that is 8-13 with 2 “Poor/Present”s or less, you should grade it as “Fair”, and if that is 14 or more, or 3 “Poor/Present”s or more, you should grade it as “Poor”.

Annex 3: Recording form for on the spot assessment

Name of Hospital: _____ Date of Assessment: ____/____/____

No	Name or Film ID	Date taken	ID marking	Patient Position.	Density	Contrast	Sharpness	Artifacts	Total Score	Overall Assessment	Solutions / Actions	
1		/ /								Ex / G / F / P		
2		/ /								Ex / G / F / P		
3		/ /								Ex / G / F / P		
4		/ /								Ex / G / F / P		
5		/ /								Ex / G / F / P		
TB supervisor:			Physician:		Radiographer:		Excellent=		Good=	Fair=	Poor=	/ Total=

Name of Hospital: _____ Date of Assessment: ____/____/____

No	Name or Film ID	Date taken	ID marking	Patient Position.	Density	Contrast	Sharpness	Artifacts	Total Score	Overall Assessment	Solutions / Actions	
1		/ /								Ex / G / F / P		
2		/ /								Ex / G / F / P		
3		/ /								Ex / G / F / P		
4		/ /								Ex / G / F / P		
5		/ /								Ex / G / F / P		
TB supervisor:			Physician:		Radiographer:		Excellent=		Good=	Fair=	Poor=	/ Total=

Name of Hospital: _____ Date of Assessment: ____/____/____

No	Name or Film ID	Date taken	ID marking	Patient Position.	Density	Contrast	Sharpness	Artifacts	Total Score	Overall Assessment	Solutions / Actions	
1		/ /								Ex / G / F / P		
2		/ /								Ex / G / F / P		
3		/ /								Ex / G / F / P		
4		/ /								Ex / G / F / P		
5		/ /								Ex / G / F / P		
TB supervisor:			Physician:		Radiographer:		Excellent=		Good=	Fair=	Poor=	/ Total=

Annex 4: Recording form for systematic review

Date of Systematic Review: ____ / ____ / ____ Sum up: Excellent= ____ Fair= ____ Poor= ____ / sub-total= ____

Name of Hospital:							Name of TB supervisor:			
Name or Film ID	Date taken	ID marking	Patient Position.	Density	Contrast	Sharpness	Artifacts	Total Score	Overall Assessment	Recommendation
1	/ /								Ex / G / F / P	
2	/ /								Ex / G / F / P	
3	/ /								Ex / G / F / P	
Excellent=							Good=	Fair=	Poor=	
II : Name of District: _____ Name of Hospital: _____ Name of TB supervisor: _____										
Name or Film ID	Date taken	ID marking	Patient Position.	Density	Contrast	Sharpness	Artifacts	Total Score	Overall Assessment	Recommendation
1	/ /								Ex / G / F / P	
2	/ /								Ex / G / F / P	
3	/ /								Ex / G / F / P	
Excellent=							Good=	Fair=	Poor=	
III : Name of District: _____ Name of Hospital: _____ Name of TB supervisor: _____										
Name or Film ID	Date taken	ID marking	Patient Position.	Density	Contrast	Sharpness	Artifacts	Total Score	Overall Assessment	Recommendation
1	/ /								Ex / G / F / P	
2	/ /								Ex / G / F / P	
3	/ /								Ex / G / F / P	
Excellent=							Good=	Fair=	Poor=	
IV : Name of District: _____ Name of Hospital: _____ Name of TB supervisor: _____										
Name or Film ID	Date taken	ID marking	Patient Position.	Density	Contrast	Sharpness	Artifacts	Total Score	Overall Assessment	Recommendation
1	/ /								Ex / G / F / P	
2	/ /								Ex / G / F / P	
3	/ /								Ex / G / F / P	
Excellent=							Good=	Fair=	Poor=	

Memo:

Memo

Memo

